



Comparative Evaluation of Resin Modified Glass Ionomer Cement (RMGIC), Dilute Silver Diamine Fluoride and Light Cure Calcium Hydroxide as Indirect Pulp Capping Agents in Primary Teeth – An in Vivo Study

¹Dr Ilokali Khala, Postgraduate Student, Department of Pediatric and Preventive Dentistry, Himachal Institute of Dental Sciences, Paonta Sahib, Himachal Pradesh, India

²Dr Ritu Mangla, Professor, Department of Pediatric and Preventive Dentistry, Himachal Institute of Dental Sciences, Paonta Sahib, Himachal Pradesh, India.

³Dr Parminder Singh Dua, Professor and Head of Department, Department of Pediatric and Preventive Dentistry, Himachal Institute of Dental Sciences, Paonta Sahib, Himachal Pradesh, India.

⁴Dr Deepa, Sr. Lecturer, Department of Pediatric and Preventive Dentistry, Himachal Institute of Dental Sciences, Paonta Sahib, Himachal Pradesh, India.

⁵Dr Syed Rumisa, Sr. Lecturer, Department of Pediatric and Preventive Dentistry, Himachal Institute of Dental Sciences, Paonta Sahib, Himachal Pradesh, India.

⁶Dr Prince Kumar, Postgraduate student, Department of Pediatric and Preventive Dentistry, Himachal Institute of Dental Sciences, Paonta Sahib, Himachal Pradesh, India.

Corresponding Author: Dr Ilokali Khala, Postgraduate Student, Department of Pediatric and Preventive Dentistry, Himachal Institute of Dental Sciences, Paonta Sahib, Himachal Pradesh, India

Citation this Article: Dr Ilokali Khala, Dr Ritu Mangla, Dr Parminder Singh Dua, Dr Deepa, Dr Syed Rumisa, Dr Prince Kumar, “Comparative Evaluation of Resin Modified Glass Ionomer Cement (RMGIC), Dilute Silver Diamine Fluoride and Light Cure Calcium Hydroxide as Indirect Pulp Capping Agents in Primary Teeth – An in Vivo Study”, IJMSIR – June – 2026, Vol – 11, Issue – 3, P. No. 01 – 09.

Type of Publication: Case Series

Conflicts of Interest: Nil

Abstract

Background: Indirect pulp capping (IPC) is a minimally invasive approach for managing deep carious lesions in primary teeth. Although calcium hydroxide has long been the gold standard, newer materials such as resin-modified glass ionomer cement (RMGIC) and silver diamine fluoride (SDF) have shown promising bioactive properties.

Aim: To evaluate and compare the clinical and radiographic efficacy of RMGIC, dilute SDF (1:10), and

light-cure calcium hydroxide as IPC agents in primary teeth.

Materials and Methods: An in vivo study was conducted on primary molars with deep carious lesions. Teeth were randomly divided into three groups: Group I – RMGIC, Group II – dilute SDF (1:10), and Group III – light-cure calcium hydroxide. Clinical and radiographic evaluations were performed at 1, 3, and 6 months.

Results: RMGIC and dilute SDF demonstrated higher success rates compared to light-cure calcium hydroxide in both clinical and radiographic parameters.

Conclusion: RMGIC and dilute SDF are effective alternatives to calcium hydroxide for IPC in primary teeth.

Keywords: Indirect Pulp Capping, RMGIC, SDF, Calcium Hydroxide, Primary Teeth

Introduction

The preservation of primary dentition is essential for maintaining arch integrity, mastication, speech development, and proper eruption of permanent teeth. Dental caries remains one of the most prevalent chronic diseases in children worldwide and is a leading cause of premature loss of primary teeth.¹

Indirect pulp capping (IPC) is a conservative vital pulp therapy indicated in teeth with deep carious lesions and reversible pulpitis. It involves selective caries removal, leaving a thin layer of affected dentin to prevent pulp exposure, followed by placement of a biocompatible material to promote healing and tertiary dentin formation. IPC has demonstrated high success rates when proper case selection and sealing are achieved.^{2,3}

Calcium hydroxide has historically been considered the gold standard for IPC due to its antibacterial properties and ability to stimulate reparative dentin formation. However, several limitations have been reported, including high solubility, poor adhesion to dentin, tunnel defects in dentin bridges, and susceptibility to microleakage, which may compromise long-term success.^{4,5}

Resin Modified Glass Ionomer Cement (RMGIC) has gained popularity due to its improved physical properties, chemical adhesion to tooth structure, fluoride release, and superior sealing ability. These properties help reduce bacterial penetration and enhance pulp protection.^{6,7}

Silver Diamine Fluoride (SDF), particularly in diluted form, has emerged as a promising material due to its potent antimicrobial action and remineralization

potential. Silver ions disrupt bacterial cell walls, enzymes, and DNA, while fluoride promotes the formation of fluorapatite, enhancing resistance to further demineralization.⁷

Despite the growing use of these materials, there is limited clinical evidence directly comparing the efficacy of RMGIC, dilute SDF (1:10), and light-cure calcium hydroxide as IPC agents in primary teeth. Therefore, the present study was undertaken to evaluate and compare their clinical and radiographic outcomes.

Materials And Methods

This in vivo clinical study was conducted in the Department of Pediatric and Preventive Dentistry, Himachal Institute of Dental Sciences, Paonta Sahib, Himachal Pradesh, India. The study protocol was approved by the Institutional Ethics Committee (Ref No: HIDS/PAO/EC/11 dated 15.02.2024). Written informed consent was obtained from the parents/guardians of all participating children prior to inclusion in the study. A total of 45 primary molars indicated for indirect pulp capping were selected from children aged 4–9 years. The teeth were randomly allocated into three groups (n = 15 each). Randomization was carried out using a chit system, wherein each participant selected a coded chit corresponding to one of the three groups.

Inclusion Criteria

- Patient with good general health.
- Clinically large carious lesion.
- History of tolerable dull intermittent pain, mild discomfort associated with eating, negative history of spontaneous pain.
- Radiolucency approximating pulp.
- Normal lamina dura and periodontal ligament space.
- No interradicular radiolucency.

Exclusion Criteria

- History of spontaneous pain or tenderness on palpation/percussion.
- Clinical examination showing presence of mobility of tooth, discoloration of tooth, or abscessed tooth.
- Radiographic examination showing carious lesion with definite pulp exposure, interrupted or broken lamina dura, widened periodontal ligament space, periapical radiolucency.
- Patient with behavioural management issues.
- Systemic diseases.

Operative Procedure

Local anesthesia was administered using 2% lignocaine with 1:80,000 adrenaline to ensure patient comfort. Rubber dam isolation was achieved in all cases to maintain a dry operating field and to prevent contamination. Caries removal was performed using a selective caries removal technique, wherein peripheral infected dentin was removed using a sterile round diamond bur in a high-speed handpiece until sound dentin was reached, while in the deeper pulpal area, caries excavation was carried out using a spoon excavator to preserve affected dentin and avoid pulp exposure.

Group I: Resin Modified Glass Ionomer Cement (RMGIC)

Following caries removal:

- The cavity was cleaned and gently dried without desiccation.
- RMGIC (Xtracem LC) was mixed according to manufacturer's instructions.
- The material was placed directly over the remaining dentin as an indirect pulp capping agent.
- Light curing was performed for the recommended duration.

- The cavity was restored with RMGIC to ensure adequate coronal seal.

Group II: Dilute Silver Diamine Fluoride (SDF) (1:10)

Following caries removal:

- The cavity was irrigated with sterile saline and gently dried.
- Dilution of SDF was prepared by mixing one drop of SDF with nine drops of distilled water (1:10 dilution).
- The diluted SDF was applied to the cavity floor using a microbrush applicator and actively rubbed for 2 minutes.
- The cavity was rinsed thoroughly and dried.
- Final restoration was performed using RMGIC.

Group III: Light-Cure Calcium Hydroxide

Following caries removal:

- Light-cured calcium hydroxide (Prevest) was applied directly over the remaining dentin using the dispensing tip.
- A uniform thickness of approximately 1 mm was maintained.
- The material was light cured according to manufacturer's instructions.
- The cavity was subsequently restored with RMGIC.

Evaluation Criteria

Clinical Parameters:

- Pain
- Sensitivity to percussion
- Swelling/fistula

Radiographic Parameters:

- Periapical radiolucency
- Internal root resorption
- External root resorption
- Furcation radiolucency
- Periodontal ligament widening

Statistical Analysis

Data were analyzed using Jamovi statistical software (version 2.6). Descriptive statistics were used to calculate frequency and percentage. Intergroup comparisons were performed using Fisher's exact test due to small sample size. A p -value < 0.05 was considered statistically significant.

Results

All three groups showed favorable outcomes over the follow-up period. At the 1-month follow-up, the SDF group showed a 100% success rate, while the RMGIC and LCCH groups demonstrated success rates of 93.3% each, with one clinical failure (6.7%) observed in both groups. Fisher's exact test revealed no statistically significant difference in clinical outcomes among the groups at this interval ($p = 1.000$).

At the 3-month follow-up, all three groups exhibited a 100% clinical success rate, with no failures recorded. At the 6-month follow-up, the RMGIC, SDF, and LCCH groups demonstrated success rates of 92.9%, 86.7%, and 85.7%, respectively, with corresponding failure rates of 7.1%, 13.3%, and 14.3%.

Clinical parameters such as pain, sensitivity, and swelling were minimal in RMGIC and SDF groups. Radiographic findings indicated better healing and fewer pathological changes in these groups.

Overall, RMGIC and dilute SDF exhibited superior performance compared to light-cure calcium hydroxide.

Discussion

Indirect pulp therapy aims to preserve pulp vitality by eliminating active caries while maintaining a protective dentin barrier. The success of IPC depends on multiple factors, including accurate diagnosis, adequate sealing, antimicrobial properties of the material, and its biocompatibility.^{8,9,10}

In the present study, all three materials demonstrated favorable outcomes; however, RMGIC and dilute SDF showed superior clinical and radiographic success compared to light-cure calcium hydroxide. Similar findings have been reported in previous clinical and systematic studies evaluating IPC materials.^{9,10,11}

The comparatively lower success observed with calcium hydroxide may be attributed to its inherent limitations. Its high solubility and lack of adhesion can result in marginal gaps, leading to microleakage and bacterial infiltration. Additionally, the formation of porous dentin bridges (tunnel defects) may further compromise pulpal healing.^{12,13} These findings are in agreement with studies by Mickenautsch et al. and Casagrande et al., who reported increased failure rates associated with calcium hydroxide over long-term follow-up.¹⁰ Further systematic reviews have also indicated a higher probability of failure with calcium hydroxide compared to other bioactive materials.¹²

RMGIC demonstrated superior outcomes in the present study, likely due to its ability to chemically bond to dentin and provide an effective seal against bacterial ingress. Its sustained fluoride release contributes to remineralization and inhibition of residual bacteria.^{13,14} Kotsanos et al. reported a success rate of 96.5% with RMGIC in primary molars, highlighting its effectiveness as both a restorative and pulp capping material.¹⁴ Similarly, studies by Metalita et al. and Korwar et al. have emphasized the biocompatibility and remineralizing potential of glass ionomer-based materials.^{7,15}

Dilute SDF (1:10) also showed favorable results in the present study. The antimicrobial action of silver ions, combined with the remineralizing effect of fluoride, creates a synergistic effect that arrests caries progression and promotes dentin hardening.^{6,16} Sinha et al. demonstrated a significant increase in fluoride ion

concentration and remineralization potential with SDF.⁶ Shafi et al. reported that dilute SDF showed comparable or better outcomes than calcium hydroxide in IPC procedures.¹⁷ Similarly, Patil et al. concluded that SDF is an effective alternative due to its strong antibacterial properties and ability to arrest caries progression.¹⁸ In this study SDF was diluted with distilled water (one drop of SDF mixed with 9 drops of distilled water giving a 1:10 dilution) to minimize black discoloration of treated tooth surfaces while preserving caries- arresting antimicrobial and remineralizing effects from silver and fluoride ions. Despite this, black discoloration was observed in all patients in the SDF group in this study. Studies by Gupta et al. have highlighted the superior antimicrobial efficacy of SDF compared to other materials.¹⁹

The improved performance of RMGIC and SDF observed in this study highlights the importance of achieving an effective seal and controlling bacterial activity within the cavity. Materials that provide both antimicrobial action and long-term sealing ability are more likely to maintain pulp vitality and prevent disease progression.^{2,10,20}

Clinically, these findings suggest that RMGIC and dilute SDF can be considered reliable alternatives to calcium hydroxide for indirect pulp capping in primary teeth. These materials not only enhance treatment outcomes but also provide additional benefits such as fluoride release and caries arrest, making them particularly suitable for pediatric patients.^{6,21}

However, certain limitations must be acknowledged. The study had a relatively short follow-up period of six months, which may not fully reflect long-term outcomes. Previous long-term studies have shown that success rates may vary over time.¹⁰ Additionally, the sample size was limited, and larger randomized controlled trials with

extended follow-up periods are required to validate these findings.

Table 1: Comparison of clinical outcome at various time intervals

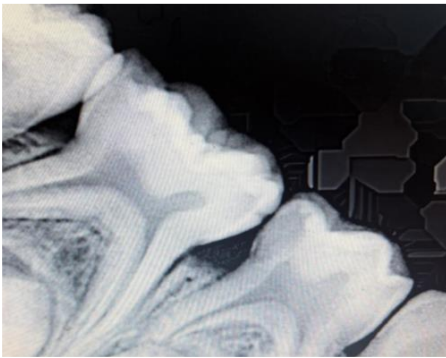
		Group			P value
		RMGIC	SDF	LCCH	
Clinical Outcome at 1 month	Success	14	15	14	1.000
		93.3%	100.0%	93.3%	
	Failure	1	0	1	
		6.7%	0.0%	6.7%	
Clinical Outcome 3 months	Success	14	15	14	—
		100%	100.0%	100%	
	Failure	0	0	0	
		0.0%	0.0%	0.0%	
Clinical Outcome 6 months	Success	13	13	12	1.000
		92.9%	86.7%	85.7%	
	Failure	1	2	2	
		7.1%	13.3%	14.3%	

Table 2: Comparison of radiographic success at various time intervals

Comparison of radiographic success at various time intervals					
		Group			P value
		RMGIC	SDF	LCCH	
Radiographic success at 1 month	Success	14	15	14	1.000
		93.3%	100.0%	93.3%	
	Failure	1	0	1	
		6.7%	0.0%	6.7%	
Radiographic Outcome 3 months	Success	14	15	14	—
		100%	100.0%	100%	
	Failure	0	0	0	
		0.0%	0.0%	0.0%	
Radiographic Outcome 6 months	Success	13	13	13	1.000
		92.9%	86.7%	92.9%	
	Failure	1	2	1	
		7.1%	13.3%	7.1%	

Case 1:

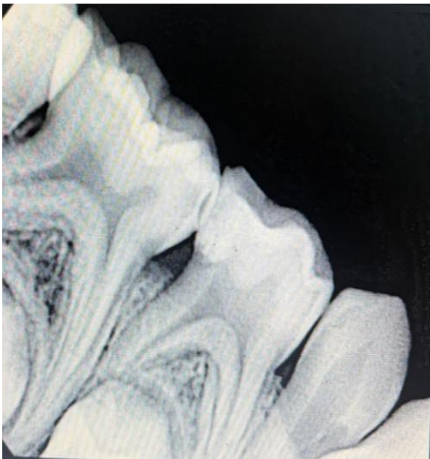
Resin Modified Glass Ionomer Cement (Group -1)



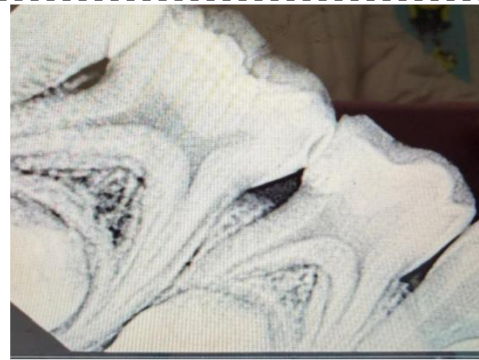a) Pre- Operative Radiograph



b) Pre- Operative Photograph



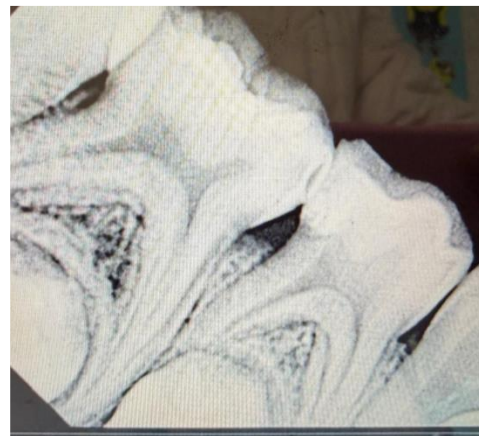
c) Post-Operative Radiograph



d) Follow Up At 3 Months



e) Follow Up At 3 Months

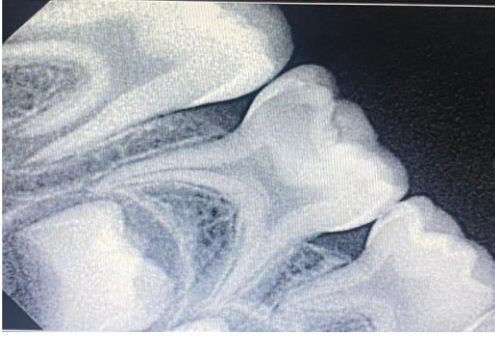

f) Follow Up At 6 Months

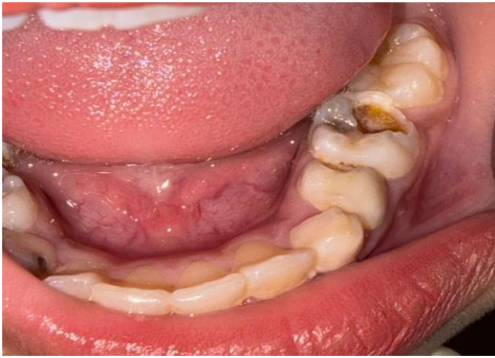Figure 1: Resin Modified Glass Ionomer Cement group. (a) Pre -operative radiograph, (b) Pre operative photograph, (c). Postoperative radiograph, (d,e,f) follow up after 1,3 6 months

Case 2:

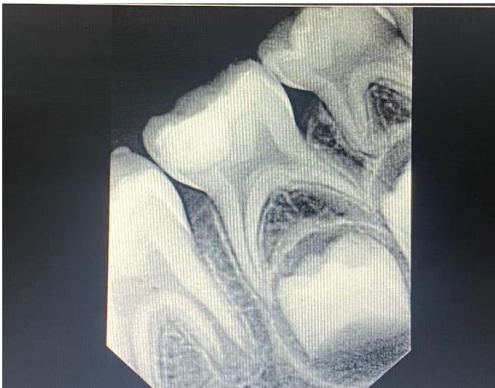Silver Diamine Fluoride (Group 2)



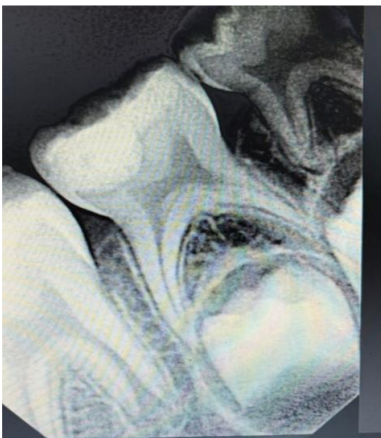a) Pre operative radiograph



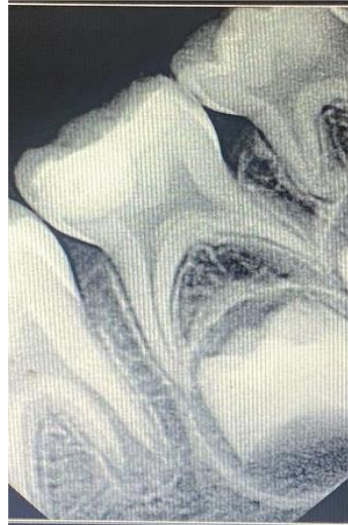
b) Pre operative photograph



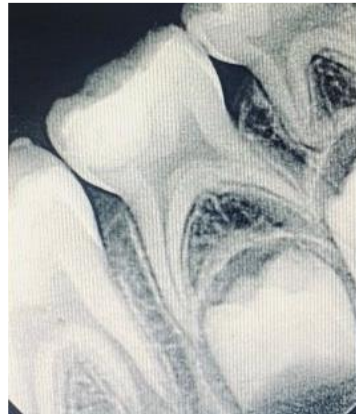
c) Post operative radiograph



d) follow up at 1 month



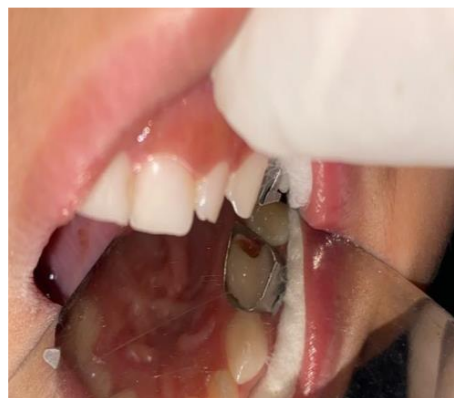e) follow up at 3 months



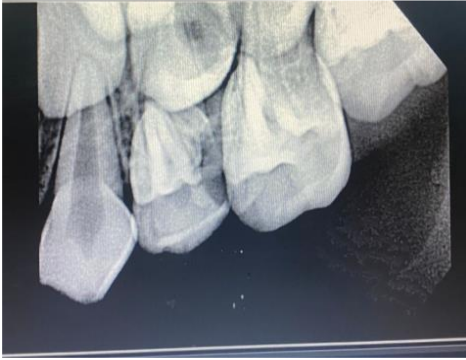f) follow up at 6 months

Figure 2: Silver Diamine Fluoride group.(a) Pre - operative radiograph, (b). Pre operative photograph, (c) Postoperative radiograph, (d, e, f) follow up after 1,3,6 months

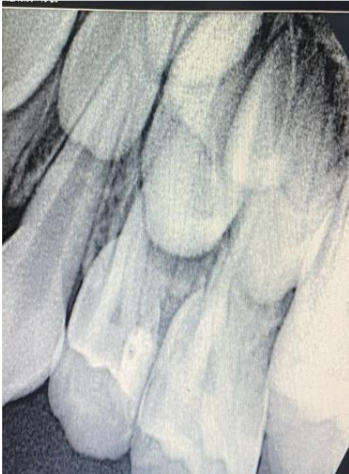Case 3: Light Cure Calcium Hydroxide.



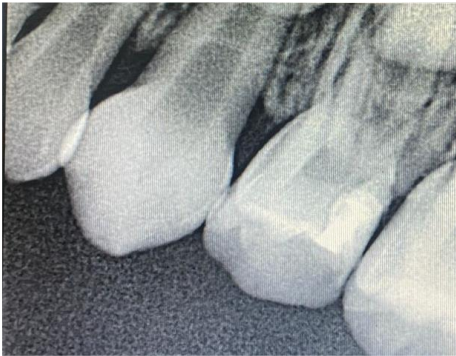a) Cavity Preparation



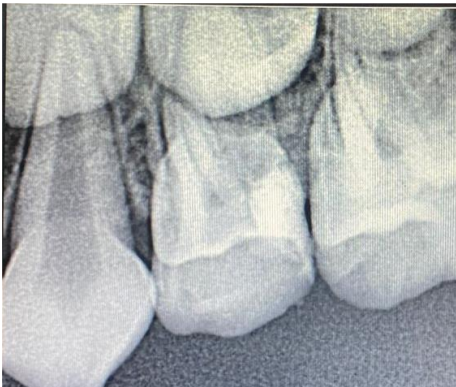b) Pre- Operative Radiograph



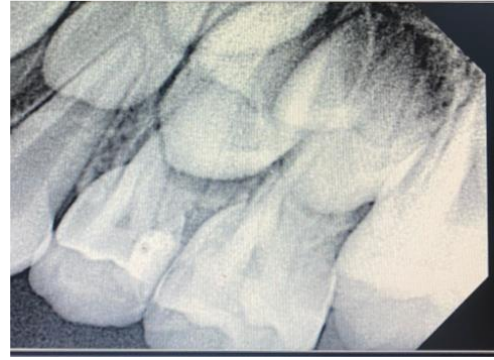c) Post Operative Radiograph



d) Follow Up At 1 Month



e) Follow Up At 3 Months



f) Follow Up At 6 Months

Figure 3: Light cure Calcium hydroxide group (a) cavity preparation, (b) Pre operative radiograph, (c). Postoperative radiograph, (d, e, f) follow up after 1,3, 6 months

Conclusion

- RMGIC and dilute SDF demonstrated superior clinical and radiographic success
- Light-cure calcium hydroxide showed comparatively higher failure rates
- RMGIC and dilute SDF can be recommended as effective IPC agents in primary teeth

Clinical Significance

The use of RMGIC and dilute SDF in IPC procedures can enhance treatment outcomes by improving sealing ability, reducing bacterial load, and promoting remineralization, thereby preserving pulp vitality.

Recommendations

- Long-term studies with larger sample sizes
- Evaluation of newer bioactive materials

References

1. Singhal M, Chaudhary C, Anand R, Singh N, Sahni T. Recent advancements of indirect pulp capping in primary teeth: a review. *J Adv Med Dent Sci Res.* 2015;3(5):S78-80.
2. Al-Zayer MA, Straffon LH, Feigal RJ, Welch KB. Indirect pulp treatment of primary posterior teeth: a retrospective study. *Pediatr Dent.* 2003;25(1):29–36.

3. Farooq NS, Coll JA, Kuwabara A, Shelton P. Success rates of formocresol pulpotomy and indirect pulp treatment in primary teeth. *Pediatr Dent.* 2000;22(4):278–86.
4. Pinto AS, Araújo FB, Franzon R, Figueiredo MC, Henz S, García-Godoy F. Clinical and microbiological effect of calcium hydroxide in deep caries lesions. *J Clin Pediatr Dent.* 2006;31(2):84–8.
5. Singhal M, Chaudhary CP, Anand R, Singh N, Sahni T. Recent advancements in indirect pulp capping in primary teeth. *Int J Clin Pediatr Dent.* 2015;8(3):217–21.
6. Sinha N, Gupta A, Logani A, Shah N. Remineralizing efficacy of silver diamine fluoride and glass ionomer type VII. *J Conserv Dent.* 2011;14(4):423–8.
7. Korwar A, Sharma S, Logani A, Shah N. Pulp response to high fluoride-releasing materials in indirect pulp treatment. *J Conserv Dent.* 2015;18(4):288–92.
8. Parisay I, Ghoddusi J, Forghani M. Vital pulp therapy in primary teeth: a review. *J Dent (Tehran).* 2015;12(6):406–17.
9. Santos PS, Pedrotti D, Braga MM, Rocha RO, Lenzi TL. Materials used for indirect pulp treatment in primary teeth: systematic review. *Int J Paediatr Dent.* 2017;27(6):451–60.
10. Casagrande L, Bento LW, Dalpian DM, García-Godoy F, Araujo FB. Indirect pulp treatment in primary molars: 60-month results. *Am J Dent.* 2010;23(1):34–8.
11. Mathur VP, Dhillon JK, Logani A, Kalra G. Evaluation of indirect pulp capping using CBCT. *Clin Oral Investig.* 2017;21(7):2123–30.
12. Santos PS, Pedrotti D, Braga MM, Rocha RO, Lenzi TL. Materials used for indirect pulp treatment in primary teeth: systematic review. *Int J Paediatr Dent.* 2017;27(6):451–60.
13. Mickenautsch S, Yengopal V, Banerjee A. Pulp response to resin-modified glass ionomer and calcium hydroxide in deep cavities. *Clin Oral Investig.* 2010;14(3):275–83.
14. Kotsanos N, Arizos S. Evaluation of resin-modified glass ionomer cement as indirect pulp therapy and restorative material in primary molars. *Eur Arch Paediatr Dent.* 2011;12(3):139–44.
15. Metalita M, Tedjosongko U, Nurain P. Indirect pulp capping treatment using glass ionomer cement in primary molars. *Dent J (Maj Ked Gigi).* 2014;47(1):18–22.
16. Shah S, Bhaskar V, Venkatraghavan K, Choudhary P, Ganesh M. Silver diamine fluoride: a review. *J Adv Oral Res.* 2014;5(1):1–6.
17. Shafi N, Kaur H, Choudhary R, Yeluri R. Comparative evaluation of dilute SDF and calcium hydroxide in primary molars. *J Clin Pediatr Dent.* 2022;46(4):230–5.
18. Patil D, Katge F, Jain K, Poojari M, Chimata VK. Comparative evaluation of SDF and calcium hydroxide in indirect pulp treatment. *Int J Clin Pediatr Dent.* 2021;14(3):378–82.
19. Gupta A, Sinha N, Logani A, Shah N. Antimicrobial efficacy of silver diamine fluoride and glass ionomer cement. *J Conserv Dent.* 2017;20(5):318–22.
20. Bressani AEL, Mariath AAS, Haas AN, García-Godoy F, Araujo FB. Incomplete caries removal and indirect pulp capping in primary molars. *J Clin Pediatr Dent.* 2013;37(4):381–6.
21. Chauhan A, Dua P, Saini S, Mangla R, Butail A, Ahluwalia S. Clinical and radiographic outcomes of indirect pulp treatment in primary teeth. *Int J Clin Pediatr Dent.* 2018;11(2):130–5.