

Sarcomatoid Urothelial Carcinoma—A case report with review of literature

¹Nanda Patil, Professor, Department of Pathology, Krishna Institute of Medical Sciences, Karad, Maharashtra.

²Parin Upadhyay, Tutor, Department of Pathology, Krishna Institute of Medical Sciences, Karad, Maharashtra.

³Supriya Karmakar, Tutor, Department of Pathology, Krishna Institute of Medical Sciences, Karad, Maharashtra.

Corresponding Author: Parin Upadhyay, Tutor, Department of Pathology, Krishna Institute of Medical Sciences, Karad, Maharashtra.

Citation this Article: Nanda Patil, Parin Upadhyay, Supriya Karmakar, “Sarcomatoid Urothelial Carcinoma—A case report with review of literature”, IJMSIR- June - 2021, Vol – 6, Issue - 3, P. No. 176 – 179.

Type of Publication: Case Report

Conflicts of Interest: Nil

Abstract

Urothelial Carcinoma is the most common type of bladder cancer. It has propensity for divergent differentiation. Sarcomatoid carcinoma is an aggressive variant of urothelial carcinoma having poor prognosis. Identification of this variant in histology is important for further management of patient. We present a case of Sarcomatoid Urothelial Carcinoma with review of literature to highlight its aggressive course.

Keywords: Urothelial Carcinoma, Sarcomatoid variant. Urinary bladder.

Introduction

Sarcomatoid Urothelial Carcinoma is a high grade malignant tumor of the bladder which reveals a malignant epithelial component along with areas having malignant spindle cells. It is an aggressive tumor having poor prognosis. Therefore identifying the tumor in histology is important for further management of patient.

Case History

60 years old male patient presented with complaints of pain in lower abdomen and hematuria since 2 months. CT abdomen and pelvis was done which revealed

neoplastic fungating growth with irregular margins arising from neck of urinary bladder. Urine examination revealed Albumin in 3+ range and 80-100 RBCs/hpf. Other investigations were within the normal limits.

Transurethral resection was done and specimen was sent for histopathological examination. Microscopy revealed a malignant tumor arranged in polypoidal, nested and glandular pattern with epithelial cells resembling urothelial morphology admixed with spindle shaped neoplastic cells. Malignant spindle cell component was undifferentiated high grade sarcoma. Both epithelial and spindle cells revealed enlarged hyperchromatic bizarre nuclei (figure 1,2,3). Heterologous element was not found in our case. Considering these features diagnosis was given as Sarcomatoid Urothelial Carcinoma without heterologous element.

Discussion

The most common type of bladder cancer is urothelial carcinoma. It accounts for 0.6% of all bladder tumors.² It is more common in male and the median age of diagnosis is 65-70 years.³ Similar observation was

noted in our case. This tumor has propensity for divergent differentiation. The examples are squamous, glandular, nested, plasmacytoid, micro papillary, lymphoepithelioma like and sarcomatoid.⁴ Dent had previously described sarcomatoid carcinoma as carcinosarcoma.⁵ Recent World Health Organization has endorsed the term sarcomatoid carcinoma. It is most frequently found on the lateral walls of bladder, followed by the dome, trigone and anterior and posterior walls and cases arising in bladder diverticula are also noted.⁶ Cancer (epithelial) and mesenchymal stem cells are the founder cells of cancer and sarcoma, which can sustain unlimited malignant growth and differentiation⁷. Recently accumulated evidence supports that sarcomatoid carcinoma is derived from a single urothelial progenitor cell with subsequent transformation into a sarcomatoid phenotype.⁸

Clinical Features

Clinical presentation of sarcomatoid carcinoma are hematuria, dysuria, nocturia, lower abdominal pain and acute retention of urine.¹ In our case the clinical presentation was lower abdominal pain and hematuria.

Gross Appearance

Lopez_ et al¹ have described the gross appearance of sarcomatoid urothelial carcinoma as large polypoidal tumor with intraluminal masses. Our case also revealed neoplastic intraluminal growth arising from neck of urinary bladder.

Microscopic Features

Microscopically sarcomatoid urothelial carcinoma shows a mixture of malignant epithelial component such as urothelial, glandular, squamous or undifferentiated coexisting with variable degrees of differentiation mixed with sarcomatous component. The latter may have a non specific spindle cell or pleomorphic morphology, sometimes showing

osteoclast like giant cells or specific mesenchymal differentiation such as rhabdomyosarcoma, osteosarcoma, chondrosarcoma, liposarcoma or undifferentiated sarcoma. Transition may be seen between two areas i.e carcinomatous and sarcomatous components suggesting that sarcomas like areas are also of epithelial in origin.⁹ Further evidence of epithelial nature is provided by immunoreactivity for keratin seen in sarcoma like component.^{10,11} On other occasion tumor may show myxoid stroma.

Differential Diagnosis

Differential diagnosis of sarcomatoid urothelial carcinoma include leiomyosarcoma, inflammatory myofibroblastic tumor and sarcomatoid prostatic carcinoma.

Immunohistochemistry helps to arrive a definitive diagnosis. Vimentin is considered as a marker of epithelial mesenchymal transition which is expressed in 100% cases of sarcomatoid urothelial carcinoma. Also expression of several cytokeratin like pancytokeratin, CK,CK20 confirms the diagnosis of this tumors.^{12,13} GATA-3 expression is present in 70% of conventional bladder urothelial carcinoma, but its expression differs among variants of urothelial carcinoma. Sarcomatoid variant shows GATA-3 positivity in only 16% of cases.¹⁴

Prognosis and Treatment

Most patients with sarcomatoid urothelial carcinoma are elderly male and show sequential involvement of ureter and renal pelvis. Metastasis develop in regional lymph nodes and distant organs either in the form of epithelial or sarcoma like component.¹⁵

Prognosis of these patients is poor and treatment is same as for high grade urothelial carcinoma of equivalent stage.¹⁶

Conclusions

Sarcomatoid urothelial carcinoma is rare type of urothelial carcinoma showing divergent differentiation. These tumors have aggressive behavior and poor prognosis. It is important to evaluate transurethral specimens carefully with thorough sampling for proper diagnosis and definitive treatment of patients.

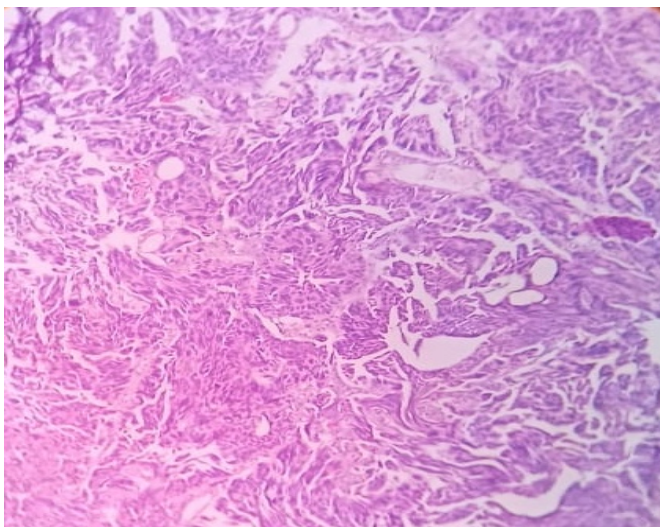


Fig. 1: Microscopy: A tumor showing biphasic pattern that is epithelial cells and spindle cells (100X,H&E)

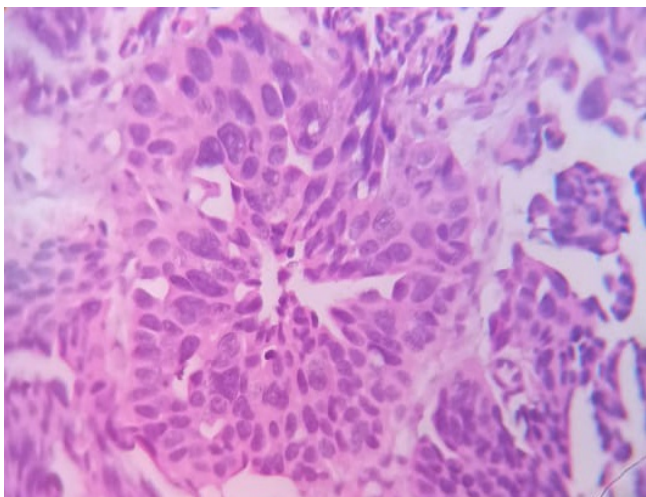


Fig.2: Microscopy: Tumor shows epithelial cells arranged in polypoidal and glandular pattern (400X,H&E)

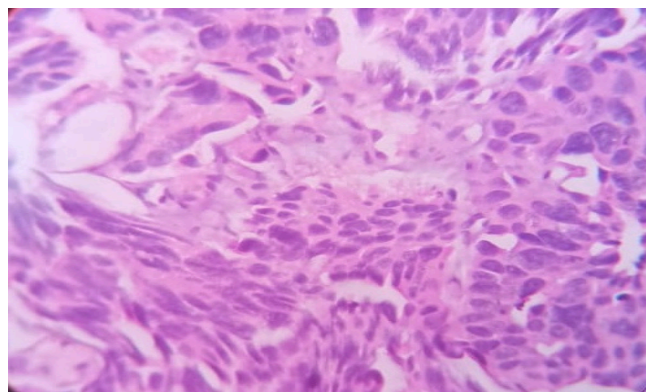


Fig. 3: Microscopy: Sarcomatoid component showing spindle shaped cells with pleomorphic bizarre nuclei (400X, H&E)

References

1. Lopez-Beltran, A. Pacelli, H. J. Rothenberg et al., "Carcinosarcoma and sarcomatoid carcinoma of the bladder: clinicopathological study of 41 cases," *J Urol*, 1998 vol. 159, (5), 1497–1503.
2. Humphrey PA, Moch H, Cubilla AL, Ulbright TM, Reuter VE. The 2016 WHO classification of tumours of the urinary system and male genital organs—part B: prostate and bladder tumours. *Eur Urol*. 2016;70:106–119.
3. Kirkali Z, Chan T, Manoharan M, et al. Bladder cancer: epidemiology, staging and grading, and diagnosis. *Urology*. 2005;66:4–34.
4. Nigwekar P, Amin MB. The many faces of urothelial carcinoma: an update with an emphasis on recently described variants. *Adv AnatPathol*. 2008;15:218–233.
5. Dent ED Jr. Carcinosarcoma (collision tumor) of the urinary bladder. *J Urol*. 1955;74:104–108.
6. Wang J, Wang FW, et al. Clinical features of sarcomatoid carcinoma (carcinosarcoma) of the urinary bladder: analysis of 221 cases. *Sarcoma* 2010.
7. Rangwala F, Omenetti A, et al. Cancer stem cells: Repair gone awry? *J Oncol*. 2011

8. Sung MT, Zhang S, et al. Histogenesis of clear cell adenocarcinoma in the urinary tract:evidence of urothelial origin. *Clin Cancer Res.*2008(14),1947-1955.
9. Jao W, Soto JM, Gould VE. Squamous carcinoma of bladder with pseudosarcomatous stroma. *Arch Pathol.* 1975;99(9):461-466.
10. Bannach B, Grignon D, Shum D. Sarcomatoid transitional cell carcinoma vs pseudosarcomatous stromal reaction in bladder carcinoma. An immunohistochemical study. *J Urol Pathol.*1993;1:105-120.
11. Torenbeek R, Blomjous CE, de Bruin PC, et al. Sarcomatoid carcinoma of urinary bladder. Clinicopathologic analysis of 18 cases with immunohistochemical and electron microscopic findings. *Am J Surg Pathol.*1994;18(3):241-249.
12. Sanfrancesco J, McKenney JK, Leivo MZ, Gupta S, Elson P, Hansel DE. Sarcomatoid urothelial carcinoma of the bladder: analysis of 28 cases with emphasis on clinico pathologic features and markers of epithelial to mesenchymal Transition.2016;140:543–551.
13. Westfall DE, Folpe AL, Paner GP, et al. Utility of a comprehensive immunohistochemical panel in the differential diagnosis of spindle cell lesions of the urinary bladder. *Am J Surg Pathol.* 2009;33:99–105.
14. Liang Y, Heitzman J, et al: Differential expression of GATA-3 in urothelial carcinoma variants. *Hum Pathol.*2014,45:1466-72.
15. Smith JA Jr, Herr HW, Middleton RG. Bladdercarcinosarcoma: Histologic variant in metastatic lesions. *J Urol.* 1983;129(4):829-831.
16. Ikegami H, IwasakiH, Ohjimi Y, et al. sarcomatoid carcinoma of the urinary bladder: a clinicopathologic and immunohistochemical analysis of 14 patients. *Hum Pathol.*2000;31(3):332-340.