

## **Epithelial Myoepithelial Carcinoma of Parotid Gland - A rare tumor with squamous differentiation**

<sup>1</sup>Nanda Patil, Professor, Department of Pathology, Krishna Institute of Medical Sciences Deemed to be University, Karad

<sup>2</sup>Avinash Mane, Assistant Professor, Department of Pathology, Krishna Institute of Medical Sciences Deemed to be University, Karad

<sup>3</sup>Supriya Karmakar, Tutor, Department of Pathology, Krishna Institute of Medical Sciences Deemed to be University, Karad

<sup>2</sup>Atul Hulwan, Assistant Professor, Department of Pathology, Krishna Institute of Medical Sciences Deemed to be University, Karad

<sup>3</sup>Robin Alexander, Tutor, Department of Pathology, Krishna Institute of Medical Sciences Deemed to be University, Karad

**Corresponding Author:** Supriya Karmakar, Tutor, Department of Pathology, Krishna Institute of Medical Sciences Deemed to be University, Karad

**Citation this Article:** Nanda Patil, Avinash Mane, Supriya Karmakar, Atul Hulwan, Robin Alexander, “Epithelial Myoepithelial Carcinoma of Parotid Gland - A rare tumor with squamous differentiation”, IJMSIR- June - 2021, Vol – 6, Issue - 3, P. No. 107 – 110.

**Type of Publication:** Case Report

**Conflicts of Interest:** Nil

### **Abstract**

**Introduction:** Epithelial Myoepithelial carcinoma is a rare malignant tumor of salivary gland, most commonly occurring in parotid gland. It is considered as low-grade malignant tumor and is seen more often in female patient in sixth decade of life.

### **Case History**

We present a rare case of Epithelial Myoepithelial Carcinoma in 62 yearold male patient who presented with parotid swelling since 6 months. Superficial parotidectomy was done. The histopathological diagnosis was low-grade Epithelial Myoepithelial carcinoma. We present this case to highlight the rarity of this tumor, squamous differentiation and unusual clinical behaviour i.e.metastasis to adjacent lymph nodes.

**Keyword:** Epithelial Myoepithelial Carcinoma, Parotid gland, Male, Squamous differentiation

### **Introduction**

Epithelial Myoepithelial Carcinoma (EMC) is a rare malignant tumor of salivary gland, which accounts for 1% of all salivary gland tumors (1, 2). Donath first introduced this tumor in 1972 (3). In 1991, WHO recognised EMC as a distinct subtype of salivary gland adenocarcinoma (4).

### **Case Report**

A 62 years old male patient presented with left sided parotid mass since 6 months. The swelling was painless in nature. CT scan revealed a well-defined isodense, solid cystic lesion with heterogeneous peripheral contrast in left parotid gland. Small subcentimetric enhancing lymphnodes were seen.

Superficial parotidectomy was done and specimen was sent for histopathological examination.

### **Histopathological Examination**

Specimen of superficial parotidectomy was received with attached lymph nodes. Gross examination revealed a tumor measuring 3.7 x 3 x 2 cms, cut section of which was solid and cystic. 4 lymphnodes were identified adjacent to the tumor tissue. (Figure 1).

Microscopy revealed a tumor showing bilayered arrangement of small luminal cells having eosinophilic cytoplasm with outer myoepithelial cells having clear cytoplasm. Tumor revealed glandular pattern with few cystic areas. Neoplastic cells revealed mild nuclear atypia and focal area of squamous differentiation. (Figure 2) No evidence of necrosis was noted. 2 out of 4 adjacent lymph nodes revealed metastasis.

PAS staining highlighted the eosinophilic basal membrane of the tubules.

Considering these features diagnosis was given as low grade Epithelial Myoepithelial Carcinoma with focal areas of squamous differentiation metastasizing to 2 out of 4 adjacent lymph nodes.

### **Discussion**

EMC is considered as a low-grade malignant tumor which may commonly recur locally after excision. This tumor is commonly seen in female patients in 6<sup>th</sup> decade of life. The patient presents as a slowly growing tumor most commonly seen in parotid gland. However, minor salivary gland are also involved in rare occasions (5).

In Contrast, our case was a male patient and the tumor progressed within 6 months. Diagnosis of EMC is based on histopathological examination. IHC markers may help to support the diagnosis. Clinical and radiological examinations as well as FNAC do not

provide a definitive preoperative diagnosis as seen in our case.

Histopathological Examination of EMC reveals a biphasic pattern of tumor with tubular, glandular or solid growth pattern. Papillary and cystic areas may be present. Depending on the proportion of epithelial and myoepithelial cells the tumor can be classified as classic or epithelial dominant or myoepithelial dominant pattern. In our case, classic pattern was seen. PAS stain highlight eosinophilic basal membrane surrounding the aggregates of tumor cells. Rarely EMC shows squamous differentiation, similar findings were noted in our case [6]. Immunohistochemistry of this tumor displays positivity for actin, P63 and S100 protein for clear cells, while epithelial ductal cells show intense staining for cytokeratin, CK7, CK5/6 and EMA.

Differential diagnosis of EMC include Pleomorphic Adenoma, Adenoid Cystic carcinoma, Acinar cell carcinoma, Mucoepidermoid carcinoma and Metastatic renal cell carcinoma. [7, 8]

The usual treatment is wide surgical excision including adjacent lymph node and follow up of case as this tumor has high rate of local recurrence [9].

Our patient is on follow up.

### **Conclusion**

EMC is a rare salivary gland neoplasm showing biphasic pattern. Histopathological examination is most important in giving definitive diagnosis. Although this tumor reveals low-grade malignant features, recurrences are common hence, post-operative follow up is recommended.

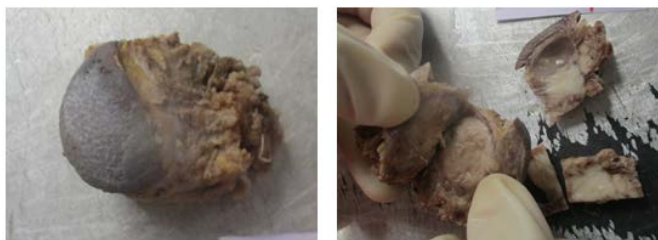

Figure 1: A grey white tumor with solid and cystic areas.

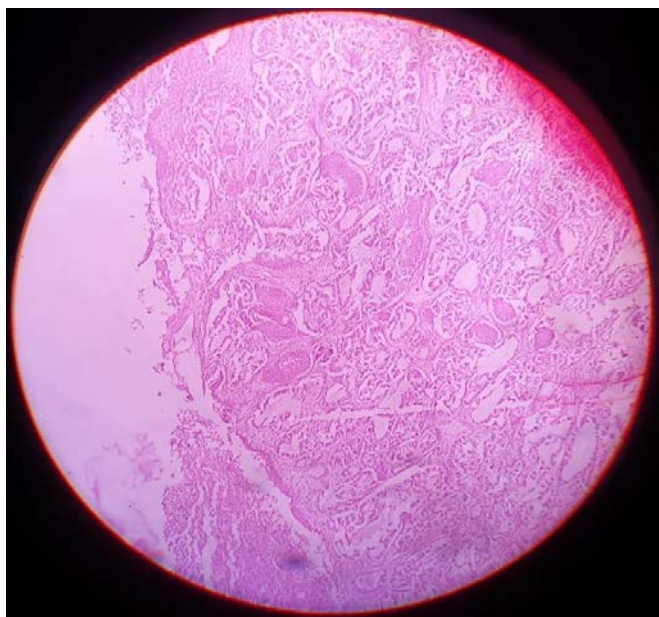


Figure 2: Microscopic features i.e. glandular pattern (100x H&E)

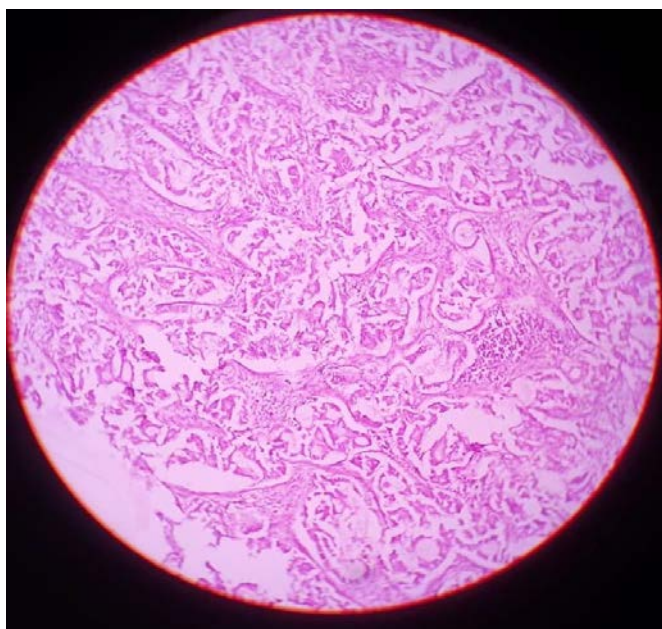


Figure 3: Biphasic appearance of tumor showing inner

epithelial cells and outer myoepithelial cells with clear cytoplasm (400 X H&E)

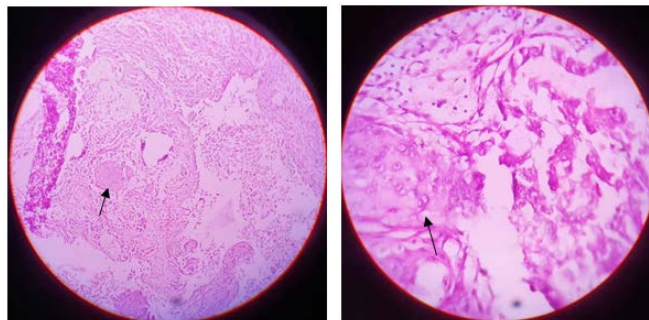


Figure 4: Neoplastic cells with squamous differentiation (A) 100x H & E (B) 400X H&E)

### References

1. Batsakis JG, El-Naggar AK, Luna MA. Epithelial–myoepithelial carcinoma of salivary glands. *Ann OtolRhinolLaryngol*1992;101:540–2.
2. Morrow TA, Chun T, Mirani N. Epithelial myoepithelial carcinoma of the parotid gland. *Ear Nose Throat J* 1990;69:646–8.
3. Donath K, Seifert G, Schmitz R. Zur Diagnose und Ultrastruktur des TubularenSpeichelgangkarzinoms. Epithelial–myoepithelial Schaltstückkarzinom. *Virchows Arch [A]* 1972;356:16–31.
4. Seifert G, Donath K. Multiple tumours of the salivary glands: terminology and nomenclature. *Eur J Cancer* 1996;32B:3–7.
5. Ellis GL, Auclair PL. Tumors of salivary glands. In: *Atlas of tumors Pathology. AFIP Third series, Fascicle 17, 1995.*
6. Raja R Seethala. New variants of epithelial–myoepithelial carcinoma: oncocytic change. *Arch pathol Lab Med* 2009;133:950 - 959
7. Hattori K, Murai N, Kusano J, Takahashi Y. Bilateral epithelial–myoepithelial carcinoma of the parotid glands. *Head Neck* 2016;38:E73-5.

8. Tralongo V, Daniele E. Epithelial–myoepithelial carcinoma of the salivary glands: a review of literature. *Anticancer Res* 1998;18:603–8.
9. Silvers A, Som P, Brandwein M. Epithelial–myoepithelial carcinoma of the parotid gland. *AJNR* 1996;17:560–2.