

Retrospective Study of Who Grade of Urothelial Carcinoma and Its Immunohistochemical Correlation with P53 and P63

Aakanksha Paniya¹, Kishore Khatri², S. R. Negi³

¹ Resident Doctor, ² Assistant Professors, ³ Senior Professor

Department of Pathology, Dr. S. N. Medical College, & Associated Group of Hospitals, Jodhpur (Rajasthan).

Corresponding Author: S. R. Negi, Senior Professor, Department of Pathology, Dr. S. N. Medical College, & Associated Group of Hospitals, Jodhpur (Rajasthan).

Type of Publication: Original Research Paper

Conflicts of Interest: Nil

Abstract

Background: Tumors of the urinary bladder contribute significantly to the human cancer burden. Cancer of the urinary bladder accounts for about 3.2% of all cancer worldwide, with an estimated 260,000 new cases occurring each year in men and 76,000 in women.

Methods: Hospital record based retrospective study conducted in the Department of Pathology, Dr. S. N. Medical College, Jodhpur. The duration of study was from January 2016 to January 2018 .

Results: A statistically significant correlation was observed between the histopathological stage and p53 immunoexpression & p63 immunoexpression.

Conclusion: Urothelial carcinoma is potentially life threatening and expensive to treat, since for many patients , the diagnosis entails a lifetime of surveillance to detect recurrent disease. Early identification of patients , whose superficial tumors will progress or recur , is very important , because changes in their treatment strategies can have a major impact on the outcome of the disease.

Keywords: p53 immunoexpression, p63 immunoexpression, Urinary bladder carcinoma.

Introduction

Tumors of the urinary bladder contribute significantly to the human cancer burden. Cancer of the urinary bladder accounts for about 3.2% of all cancer worldwide, with an estimated 260,000 new cases occurring each year in men and 76,000 in women. It occurs more commonly in males. (Male to female ratio=3:1 to 9:1). (1,13,30,43). It is ninth most common cancer in Indian Males accounting for 3.9% of all cancer cases.¹

Tobacco smoking , occupational exposure to aniline dyes, phenacetin use and chronic cystitis caused by Schistosoma Haematobium are some of the risk factors for development of bladder carcinoma. The risk of bladder cancer in smokers in 2-6 fold that of non-smokers. The risk increases with increasing duration of smoking.²

The highest incidence is in the sixth and seventh decades of life. Most patients with urothelial tumors present with at least microscopic haematuria. The most common presenting symptom of bladder carcinoma is painless gross haematuria which occurs in 85% of patients . Painful micturition, frequency, urgency and dysuria are some of other symptoms . In cases of advanced disease ,

weight loss, abdominal or bone pain may be present due to metastases.²

Mutated p53 gene is a common genetic abnormality in urothelial carcinoma of the bladder. Some studies have depicted that over expression of p53 occurs in higher stages and grades of urothelial carcinoma and over expression of the p53 gene product has been reported as a marker of progression in urothelial carcinoma. p63, a member of the p53 gene family, encodes multiple proteins that may either transactivate p53 responsive genes or act as a dominant-negative factor toward p53. p63 is regulated in bladder carcinogenesis and p63 expression is lost in most invasive cancers whereas non invasive tumors maintain p63 expression. p53 and p63 immunohistochemistry is suggested to be helpful to distinguish dysplastic changes and carcinoma in situ from reactive atypia.^{3,4}

Material and Methods

The study entitled "Retrospective Study Of Who Grade Of Urothelial Carcinoma And Its Immunohistochemical Correlation With P53 And P63." Was conducted in the Department of Pathology, Dr. S. N. Medical College, Jodhpur. The duration of study was from January 2016 to January 2018.

The following features were noted:

Name, age and sex of patient. The study also evaluated the age and sex incidence and its correlation with histological grade of urothelial carcinoma. Immunohistochemical study with p63 and p53 was also performed.

Histological findings including grading based on WHO classification will be noted and p53 and p63 labelling index and its correlation with histological grade will be done.

Inclusion Criteria

The relevant requisition forms received (during the Period of study) from Department of urology Dr. S. N. Medical College Jodhpur were included.

Exclusion Criteria

1. Those patients whose complete required data is not mentioned in the requisition form.
2. Proper tissue not identified (only necrotic material)
3. On biopsy diagnosis is other than urothelial carcinoma.

Methodology with Elaboration

As per the Department procedure the details of the specimens were checked as per the requisition form and registration number allotted to each. This information was recorded in the receipt register. All the relevant information i.e. Age, Name, type of specimen (Biopsy) was obtained from the requisition form. Additional requirement if any was also obtained from the relevant hospital from where tissue was sent.

The specimen received in the Department were fixed in 10% formalin for 24 hours. Thereafter, thorough gross examination was carried out and from every specimen, single or multiple sections were taken from representative area for histopathological examination. These sections were further processed in automated tissue processor through 3 basic steps of dehydration in alcohol, clearing with xylene and impregnation with paraffin.

After processing, sections were embedded in paraffin to make paraffin blocks. These blocks were cut serially at 3 to 5-micron thickness using rotatory microtome to prepare slides. Slides were stained with routine hematoxylin and eosin stain (Harris Method) and then mounted with DPX.

If required the preserved blocks of the tissue were also be used for preparing additional slides which were also be stained with Hematoxylin and eosin method.

Measurement of index

Nuclear staining for p53 and p63.

- p53 was evaluated according to number of positive cells no staining (0 ; Negative) ,(1+; <5% cells, weak), (2+; 5% - 75% cells, moderate), (3+; >75% cells, strong)
- p63 was evaluated according to the percentage of positive cells, (1+; 1% - 10%), (2+; 11% - 50%), and (3+; more than 50%).

Observations and Results

Table 1:Age wise distribution of cases of urinary bladder tumors (n=50)

Age (yrs)	No. of patients	Percentage
28-40	8	16.00
41-50	9	18.00
51-60	8	16.00
61-70	13	26.00
71-80	9	18.00
81-90	3	6.00
Total	50	100.00

In our study the maximum number of cases were found to be in the age group of 61-70 years.

Table 2: Gender wise distribution of cases of urinary bladder tumors (n=50)

Gender	No. of patients	Percentage
Male	43	86.00
Female	7	14.00
Total	50	100.00

In our study the maximum number of patients were males (86%)

Table 3:Distribution of urinary bladder tumors on different stages in relation to mean and standard deviation p53 labelling index

Histological stage	No. of patients	Mean+SD p53 labelling index
pT1	23	26.86+22.66
pT1a	4	10.75+9.91
pT2	7	44.42+29.64
pT3	12	80.41+10.32
pT4	2	57.5+45.96

p value <0.0001

Maximum mean p53 labelling index and standard deviation was found in pT3 (80.41+10.32).

According to one way annova, a statistically significant correlation was observed between the extent of tumor invasion (histopathological stage) and p53 immunoexpression. (p<0.0001).

Table 4:Distribution of urinary bladder tumors on different stages in relation to mean p63 labelling index and standard deviation

Histopathological stage	No. of patients	Mean+SD p63 labelling index
pT1	23	33.69+17.88
pT1a	4	69.5+19.26
pT2	7	32.85+35.41
pT3	12	12.16+18.29
pT4	2	47.5+17.67

p value 0.0007

All the stages the maximum p63 labelling index was found in pT1a (69.5+19.26). According to one way annova, a statistically significant correlation was observed between extent of tumor invasion (histopathological stage) and p63 immunoexpression. (p 0.0007)

Table 5: Distribution of urothelial tumors of different grades in relation to mean p53 labelling index

Histological diagnosis	No. of patients	Mean±SD p53 labelling index
Inverted Papilloma	2	5±2.82
PUNLMP	3	6±3.46
HGUC	19	80.52±9.98
LGUC	26	19.38±3.76

<0.0001

Amongst all grades the maximum mean p53 labelling index was found in high grade urothelial carcinoma (86%). According to one way annova, a statistically significant correlation was observed between the histopathological grade and p53 immunoexpression.(p<0.0001)

Table 6: Distribution of urothelial tumors of different grades in relation to mean p63 labelling Index

Histological diagnosis	No. of patients	Mean±SD p63 labelling index
Inverted Papilloma	2	87.5±3.53
PUNLMP	3	77.66±12.50
HGUC	19	11.57±15.67
LGUC	26	41.19±19.46

P<0.0001

Amongst all grades the maximum mean p63 labelling index was found in PUNLMP. According to one way annova, a statistically significant correlation was observed between the histopathological grade and p63 immunoexpression.

Discussion

Bladder cancer remains a disease with remarkable heterogenicity and survival outcomes. The clinical management of bladder tumors is problematic because of the difficulty in predicting the tumors in predicting the tumor profile in given patients. Histopathological examination is most helpful in timely diagnosis of

urothelial carcinoma. In recent era the most helpful tool of diagnosis is immunohistochemical analysis. This method of examination helps in early and confirm diagnosis of urothelial carcinoma according to the grades and helpful in early treatment and better prognosis. Here we have used p53 and p63 in diagnosis of urothelial carcinoma.

According to our study, a statistically significant correlation was observed between the histopathological stage and p53 immunoexpression. (p<0.0001).

Korkolopoulou et al.⁵ stated that the observance of p53 expression in advanced stages supports a crucial role for p53 mutations in bladder cancer progression. Although there is an undisputed relationship between p53 positivity and high histological grade, p53 expression can decrease in retrospective studies as paraffin embedded tissues may lost their immunoreactivity in time. Our finding that increased p53 expression with increased histological grade and invasion depth of the tumor also supports the role of p53 mutations in Urothelial Carcinoma progression.

According to our study, a statistically significant correlation was observed between histopathological stage and p63 immunoexpression. (p 0.0007)

In the current study, p63 was expressed in all cases of non-invasive papillary urothelial carcinoma and the reaction ranged from moderate to strong in most of the cells. Similar findings were reported by Urist et al.⁶who found that low-grade papillary superficial bladder tumors expressed p63 in 93% of tumor cells. However in the high-grade superficial tumors, there was a significant reduction in p63 positivity to 68%.

Many previous studies have demonstrated that the rate of p53 expression in the patients with high grade tumor is higher than in patients with low grade tumor.^{7,8}

Ye et al, have reported 40.8% and 78% p53 protein positive staining in low and high grade tumors respectively.⁹

In a study by Mellon et al¹⁰, there was strong positive correlation between the expression of mutant p53 protein and tumor stage, with none of the 18 pTa and pT1 tumors being positive for mutant p53 compared with 7 of 15 muscle invasive tumors. ($p < 0.01$) (66)

In a study of bladder tumors by Thomas DJ et al, the degree of p53 staining varied from 1% to 90% of the cells. All G3 tumors were p53 positive compared with 8 of 17 G1/G2 tumors. This difference was statistically significant using Fischer's exact test ($p = 0.011$) (100)

In a study of 212 bladder cancer biopsies specimens conducted by Lipponen PK et al.¹¹ percent of tumors were positive for p53 protein, and overexpression was associated with high histological grade, non papillary growth architecture, muscle invasiveness, dense inflammatory cell reaction, DNA aneuploidy, high S-phase fraction and high mitotic frequency. Progression in T, N and M categories was significantly related to overexpression of p53 protein.

Conclusion

A statistically significant correlation was observed between the histological grade and stage of urothelial tumors and mean p53 and p63 labelling indices. Urothelial carcinoma is potentially life threatening and expensive to treat, since for many patients, the diagnosis entails a lifetime of surveillance to detect recurrent disease. Early identification of patients, whose superficial tumors will progress or recur, is very important, because changes in their treatment strategies can have a major impact on the outcome of the disease.

References

1. Lynch CF, Cohen MB, Urinary System, Cancer 1995;75:316-29.
2. Eble J N, Sauter G, Epstein J I, Sesterhenn I A (Eds.): World Health Organisations Classification of Tumors. Pathology and Genetics of Tumors of the Urinary System and Male Genital Organs. IARC Press: Lyon 2004.
3. Cina, S.J., Epstein, J.I., Endrizzi, J.M., Harmon, W.J., Seay, T.M. and Schoenberg, M.P. (2001) Correlation of Cystoscopic Impression with Histologic Diagnosis of Biopsy Specimens of the Bladder. Human Pathology, 32, 630-637.
4. Di Como, C.J., Urist, M.J., Babayan, I., Drobnjak, M., Hedvat, C.V., Teruya-Feldstein, J., Pohar, K., Hoos, A. and Cordon-Cardo, C. (2002) p63 Expression Profiles in Human Normal and Tumor Tissues. Clinical Cancer Research, 8, 494-501.
5. Korkopoulou, Serth J, Hervatin C, Arndt H, Derendorf L, Thon WF, Jonas U. Detection of p53 tumor suppressor-gene protein in bladder tumors and prostate cancer: possible clinical implications. World J Urol. 1994;12(6):345-51.
6. Urist, M.J., Di Como, C.J., Lu, M.L., Charytonowicz, E., Verbel, D., Crum, C.P., Ince, T.A., McKeon, F.D. and Cor- S. Abdel Raheem et al. 193 don-Cardo, C. (2002) Loss of p63 Expression Is Associated with Tumor Progression in Bladder Cancer. The American Journal of Pathology, 2002,161, 1199-1206.
7. Kong G, Shin KY, Oh YH, Lee JJ, Park HY, Woo YN, Lee JD. Bcl-2 and p53 expression in invasive bladder cancers. Acta Oncol. 1998;37(7-8):715-20.
8. Kuezyk MA, Serth J, Hervatin C, Arndt H, Derendorf L, Thon WF, Jonas U. Detection of p53 tumor suppressor-gene protein in bladder tumors and

prostate cancer: possible clinical implications. *World J Urol.* 1994;12(6):345-51.

9. Nese, N., Gupta, R., Bui, M.H. and Amin, M.B. (2009) Carcinoma in Situ of the Urinary Bladder: Review of Clinicopathologic Characteristics with an Emphasis on Aspects Related to Molecular Diagnostic Techniques and Prognosis. *Journal of the National Comprehensive Cancer Network*, 2009, 7, 48-57.(20)
10. Mellon K, Wilkinson S , Vickers J , Robinson MC , Shenton BK , Neal DE. Abnormalities in p53 and DNA content in transitional cell carcinoma bladder. *Br. J Urol.* 1994 May;73(5):522-5.

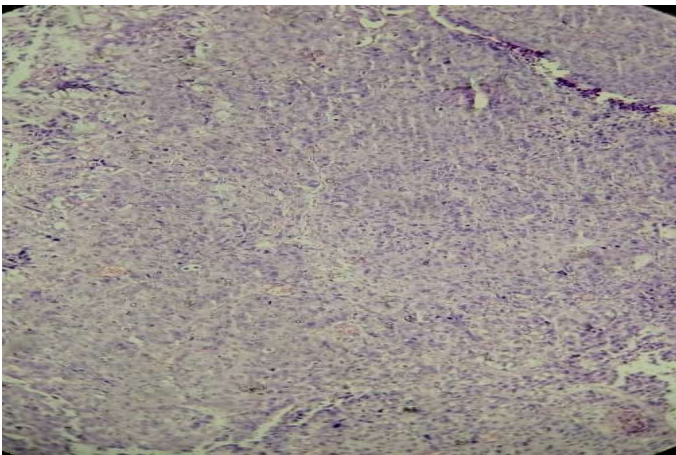


Figure 1: H and E image of High grade urothelial carcinoma 100x

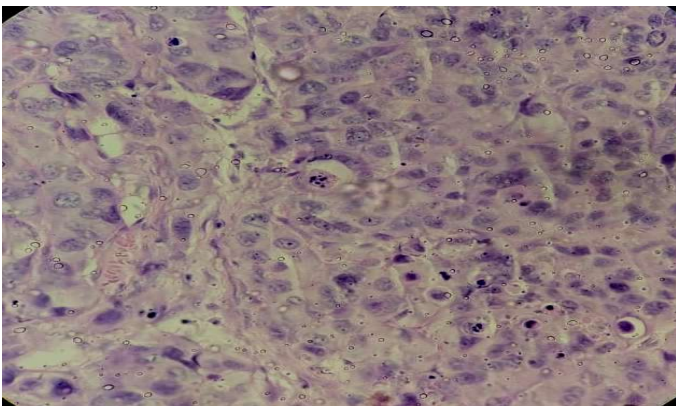


Figure 2: H and E image of High grade urothelial carcinoma 400x

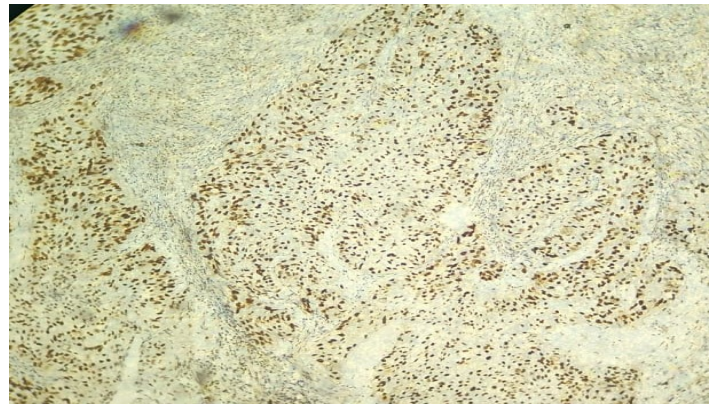


Figure 3: 3+ Scoring of immunoexpression of p53 in high grade urothelial carcinoma 100x

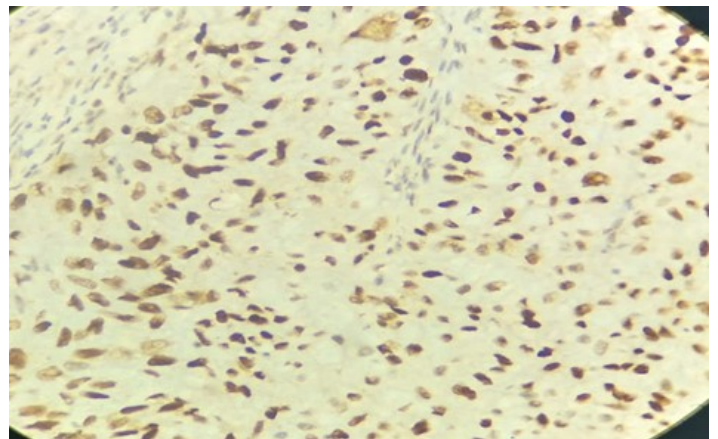


Figure 4: 3+ Scoring of immunoexpression of p53 in high grade urothelial carcinoma 400x

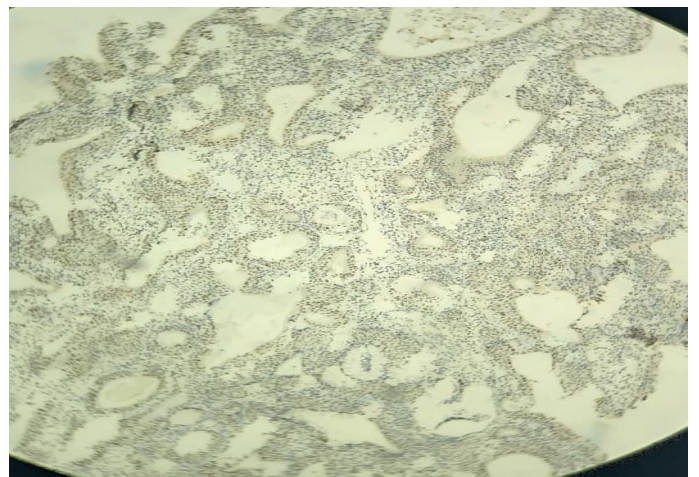


Figure 5: Negative immunoexpression of p53 in inverted papilloma 100x

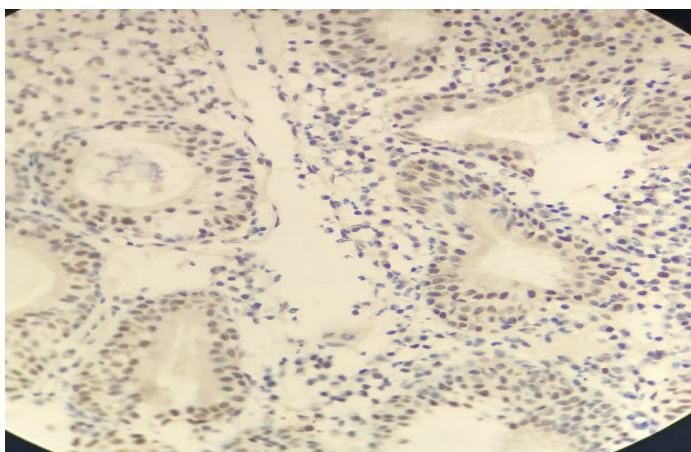


Figure 6: Negative p53 immunohistochemical expression in inverted papilloma 400x

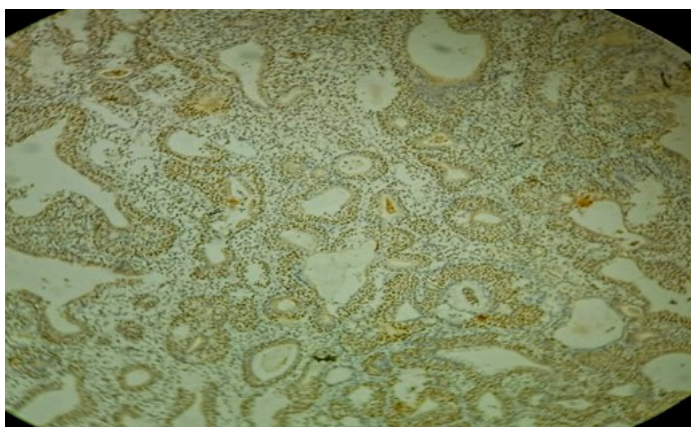


Figure 7: Intense p63 immunohistochemical expression in Inverted Papilloma 100x

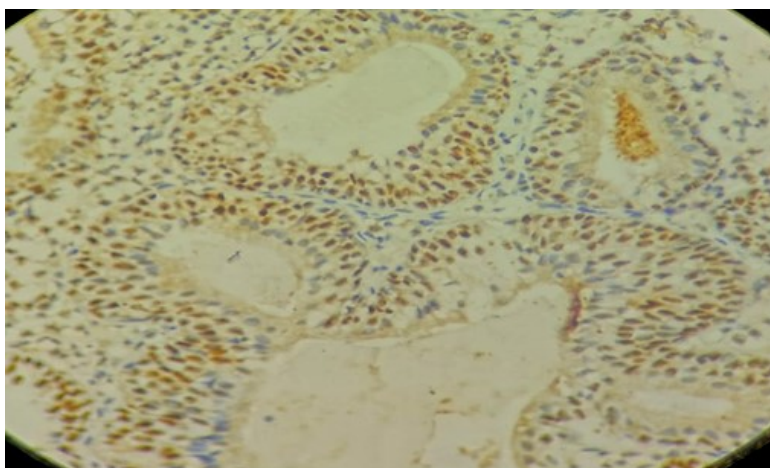


Figure 8: Intense p63 immunohistochemical expression in Inverted Papilloma 400x