

Case Report: Pelvic Neuro fibroma

Ravi Goyal¹, Vanita kumar², Neelu gupta³

Resident Doctor¹, Professor², Professor & HOD³

Department of Pathology, Sardar Patel Medical College & Associated Group of Hospital Bikaner-Rajasthan.

Corresponding Author: Vanita kumar, Professor, Department Of Pathology, Sardar Patel Medical College & Associated Group of Hospital Bikaner-Rajasthan.

Type of Publication: Case Report

Conflicts of Interest: Nil

Abstract

A 30 Yrs female patient presenting initially to gynecologist for left ovarian mass and bilateral sciatica but on further investigations it had been proved to be a big pelvic neurofibroma .Surgical excision had been done without any complications. We aim to discuss the manifestations of neurofibromatosis and why lack of some findings in the current case with the role of neuroimaging in diagnosis of the case.

Keyword- Neurofibroma, Ovarian cancer, ganglion.

Introduction

Various types of neurogenic tumors can affect the abdomen and pelvis. These tumors can be classified as being of ganglion cell origin (ganglioneuromas, ganglioneuroblastomas, neuroblastomas), paraganglionic system origin (pheochromocytomas, paragangliomas), or nerve sheath origin (neurilemmomas, neurofibromas, neurofibromatosis, malignant nerve sheath tumors) ¹ . These neurogenic tumors usually follow the distribution of the sympathetic ganglia along paraspinal areas or arise from the adrenal medulla or the organ of Zuckerkandl. Occasionally, however, other sites (eg, urinary bladder, bowel wall, abdominal wall, gallbladder) can be involved ². The urinary bladder is an unusual site of involvement

because the trigone of the bladder contains cells of neural crest origin.

Case Report

A 30 Yrs female patient complaining swelling of lower abdomen since last one month. Patient also complaining of urgency in urination, and backache.

She was subjected to USG examination which revealed bilateral hydronephrosis, right side more than left.

CT scan showed large extensive solid cystic mass in pelvic compressing bilateral lower ureters leading to moderate proximal bilateral hydronephrosis. Mass measuring 148 ×115 mm, ovaries are not separately defined; Suggestive of mitotic etiology-? carcinoma ovary. Then, she was referred to oncology department.

CA-125 level was 8.34U/ml (normal).

Blood urea level was 51.09 mg/dl and creatinine level was 2.89 mg/dl.

FNAC showed hypocellular smear consist of few clusters of spindle cell with round to oval nuclei. Suggestive of benign spindle cell mesenchymal tumour- ? fibroma.

Histology section shows spindle cells arranged in whorled pattern with areas of collagenization, myxoid change & tiny vascular channels proliferation. Spindle cells shows round to oval nucleus, many cells shows

serpentine or wavy nucleus. These histopathological features are consistent with Neurofibroma. Immunohistochemistry showed S 100 positivity and was negative for smooth muscle actin and activin receptor like kinase. This confirmed the diagnosis of Neurofibroma.



Fig.1: gross of Neuro fibroma

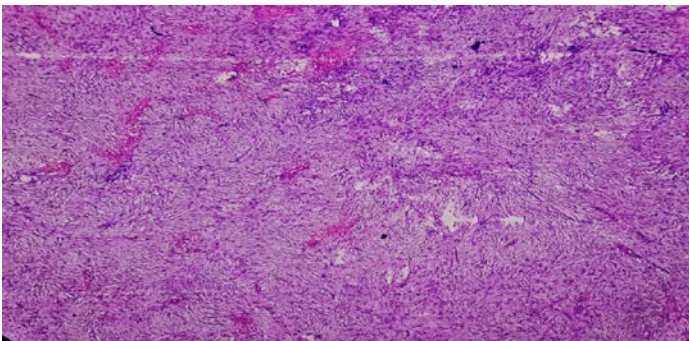


Fig.2: Histopathology of Neuro fibroma (H & E 10x)

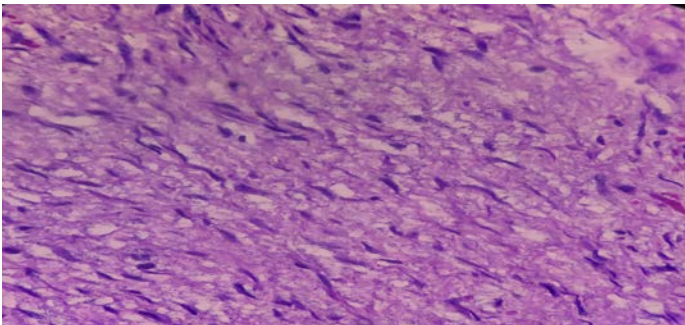


Fig.3: Histopathology of Neurofibroma (H & E 40x)

Discussion

The NF gene is found on chromosome 17 and encodes a protein called neurofibromin, which is a tumor suppressor^{4,5}. Mutations in this gene can result in decreases of this protein by different amounts, leading to

development of different types of NF and to the various tumoral lesions seen in NF.

The diagnostic criteria for neurofibromatosis1, developed by the National Institutes of Health (NIH) Consensus Conference in 1987, are based on clinical findings. The hallmark features of the disorder are CALMs and neurofibromas⁶. The NIH criteria are highly sensitive and specific in all age groups except in young children. DeBella et al.,⁷ showed that 97% of children older than 8 met the diagnostic criteria, but children under 8 years old often do not; therefore, these criteria may need to be modified for children in this age group.

Neurofibromas can grow focally or spread along the length of the nerve⁸. These tumors most commonly form in the skin but can grow anywhere in the peripheral nervous system and can involve any organ. Plexiform neurofibromas can cause complications such as pain, nerve root and spinal cord compression, and vertebral erosion⁹. Both subcutaneous and plexiform neurofibromas have the potential to transform into malignant peripheral nerve sheath tumors (MPNSTs)¹⁰. The overall risk of malignancy in neurofibromatosis-1 patients is 2.5 to 4 times more than that of the general population, but this increased risk applies only to brain and connective tissue tumors¹⁰. Interestingly, the risk of cancer is higher in female neurofibromatosis-1 patients versus males².

Neurofibromas in the retroperitoneal and pelvic regions may cause ureteric or urethral obstruction and result in hydronephrosis³. These tumors may pose difficulty for catheterization. Our patient sought gynecologic advice at first.

Conclusion

Complete resection is recommended to prevent the local recurrence and malignant transformation. FNAC is highly recommended for diagnosis and preoperative assessment.

References

1. FOX C.H., TOMAJIAN S., KAYE A.J., RUSSO S., ABADIE J.V. and KAYE A.D.: Perioperative Management of Neurofibromatosis Type 1. *The Ochsner Journal*, 12: 111-121, 2012.
2. SARICA F.B., CEKINMEZ M., TUFAN K., ERDOGAN B., SEN O. and ALTINORS M.N.: A Rare Case of Massive NF1 with Invasion of Entire Spinal Axis by Neurofibromas: Case Report. *Turkish Neurosurgery*, Vol. 18, No. 1, 99-106, 2008.
3. TOPSAKAL C., EROL F.S., OZERCAN I., MURAT A. and GURATES B.: Presacral Solitary Giant Neurofibroma Without Neurofibromatosis Type 1 Presenting as Pelvic Mass, Case Report, *Neurol. Meel. Chir. Tokyo*, 41: 620- 625, 2001.
4. GUTMANN D.H., AYLSWORTH A., CAREY J.C., KORF B., MARKS J., PYERITZ R.E., RUBINSTEIN A. and VISKOCHIL D.: The diagnostic evaluation and multidisciplinary management of neurofibromatosis 1 and neurofibromatosis 2. *JAMA*, 278: 51-57, 1997.
5. HIRSCH N.P., MURPHY A. and RADCLIFFE J.J.: Neurofibromatosis: Clinical presentations and anaesthetic implications. *Br. J. Anaesth.*, 86: 555-564, 2001.
6. National Institute of Health Concensus Development Conference: Neurofibromatosis Conference Statement. *Arch. Neurol.*, 45: 579-588, 1988.
7. DEBELLA K., SZUDEK J. and FRIEDMAN J.M.: Use of the National Institutes of Health criteria for diagnosis of neurofibromatosis 1 in children. *Pediatrics*, 105 (3): 608-614, 2000.
8. FERNER R.E.: Neurofibromatosis 1 and neurofibromatosis 2: A twenty first century perspective. *Lancet. Neurol.*, 6 (4): 340-351, 2007.
9. De SCHEPPER S., MAERTENS O., CALLENS T., NAEYAERT J.M., LAMBERT J. and MESSIAEN L.: Somatic mutation analysis in NF1 cafe' au lait spots reveals two NF1 hits in the melanocytes. *J. Invest. Dermatol.*, 128 (4): 1050-1053, 2008.
10. LE L.Q., SHIPMAN T., BURNS D.K. and PARADA L.F.: Cell of origin and micro-environment contribution for NF1-associated dermal neurofibromas. *Cell. Stem. Cell. May*, 8, 4 (5): 453-463, 2009.