

Efficacy of the Tent-Pole Technique in Vertical & Horizontal Ridge Augmentation: A Case Report

¹Dr. Shalaka Suhas Jadhav, ²Dr. Diksha Mahesh Asrani

Corresponding Author: Dr. Shalaka Suhas Jadhav

Citation this Article: Dr. Shalaka Suhas Jadhav, Dr. Diksha Mahesh Asrani, “Efficacy of the Tent-Pole Technique in Vertical & Horizontal Ridge Augmentation: A Case Report”, IJMSIR- August - 2022, Vol – 7, Issue - 4, P. No. 136 – 140.

Type of Publication: Case Report

Conflicts of Interest: Nil

Abstract

Background: Tent pole technique has also been used for bone regeneration. It is a safe and effective method for augmentation of bone height in resorbed ridges. The main advantages of tent pole technique are stable gains in Vertical/Horizontal alveolar bone height, successful retention of implant prosthesis associated with the procedure.

Aim: To evaluate the efficacy of the Tent-pole technique for ridge augmentation prior to implant placement.

Materials& Methods: A 25year old patient reported to Department of Periodontics with chief complaint of missing upper left central incisor since 3 month. Patient had history of implant placement with same region, the tent-pole technique was applied at defect sites. Bone regeneration of horizontal deficient alveolar ridge was done to prepare implant site using sticky bone with Osteon-II Bone graft and platelet rich fibrin (PRF) membrane.

Result: The mean bone height value after 4 months was found to be statistically significant with the mean bone height value preoperatively and immediate post-operative. Also, there was statistically significant difference in the mean bone density between the 4 months post-operative and immediate post-operative value.

Conclusion: The tent-pole technique is an effective method for increasing the horizontal ridge dimension, minimizing postoperative complications, and facilitating subsequent implant placement.

Keywords: PRF, Mouth Mirror, UNC-15

Introduction

- Tent pole technique has also been used for bone regeneration.
- It is a safe and effective method for augmentation of bone height in resorbed ridges.
- The main advantages of tent pole technique are stable gains in vertical as well horizontal alveolar bone height, successful retention of implant prosthesis associated with the procedure.
- Since this technique is a safe and effective method for augmentation of bone height in horizontally/vertically deficient alveolar ridge.
- Alveolar bone is a tooth dependent structure and, therefore, after a tooth is extracted dimensional bone reduction takes place both, horizontally and vertically resulting in changes that may lead to esthetic and functional problems.
- A deficient alveolar ridge fails to provide sufficient support and retention for dentures.

- This will not only compromise the soft tissue support and lower anterior facial height but also preclude dental implants placement.
- Such deformities of the alveolar ridge may compromise future implant placement as well as esthetic results when a fixed partial denture is constructed in a visible area.

Aim

To evaluate the efficacy of the Tent-pole technique for ridge augmentation prior to implant placement.

Materials & Method

- Material
- Mouth Mirror
- UNC-15 Graduated Periodontal Probe
- Osteon-II Bone Graft
- PRF Membrane

Case Report

A 25 year old patient reported to Department of Periodontics with chief complaint of missing 21 upon clinical and radiographical examination (using CBCT) since 3 month.

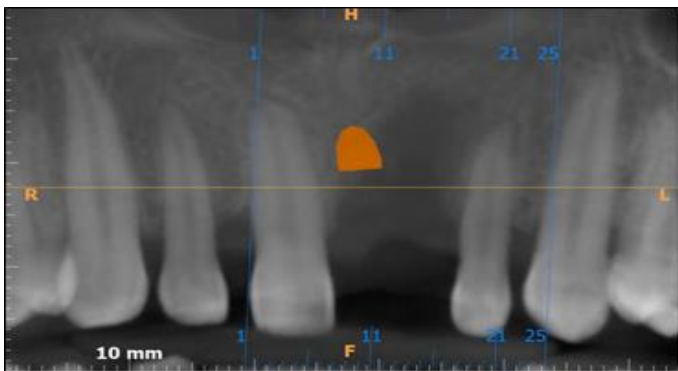


Fig.1: Pre-Operative Radiograph with 21

Surgical Procedure

- Preparation Of PRF Membrane & Sticky Bone
- Before surgery; blood sample was taken from patients forearm & collected into 2 test tubes.

- Blood in test tube-I was used to make PRF membrane by spinning in centrifuge (Choukroun PRF Machines) while
- Blood in test tube-II used to prepare PRF which mixed with osteon-II Bone graft to form sticky bone.

Procedure

- On the day of surgery; Patient was made to rinse 2% chlorhexidine rinse was given for 2minutes, followed by extraoral scrubbing with betadine scrub.
- 2% Lignocaine hydrochloride with 1:80000 adrenaline local anesthetic solution was administered at surgical site.
- A crevicular & mid crestal incision at midline of ridge with vertical releasing incision were given; full thickness mucoperiosteal flap was reflected.

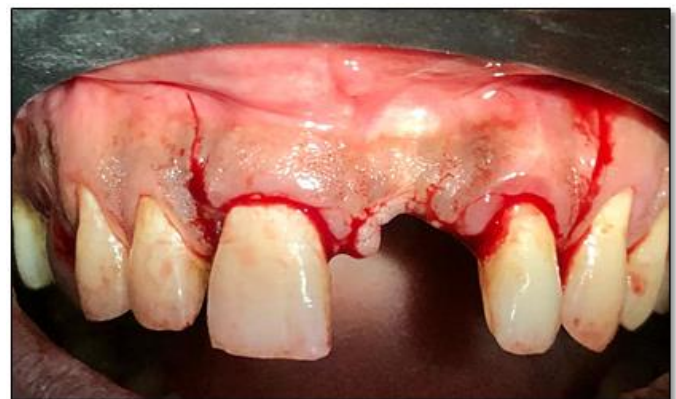

Fig. 2: Crevicular, Mid crestal and vertical releasing incision with 12 to 22 regions.

- Osteotomy was performed & tenting screw placed

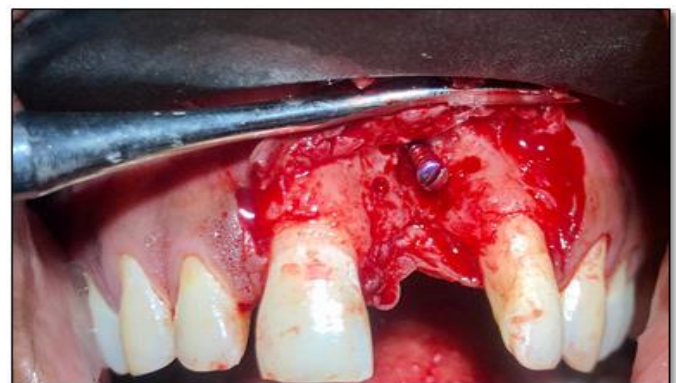

Fig.3: Osteotomy performed and tenting screw place

- Tissue undermining was performed before screw or graft placement for tension free flap closure.
- Tenting screw/titanium screw of 1.5mm of width & 8mm of height were placed in alveolar bone.

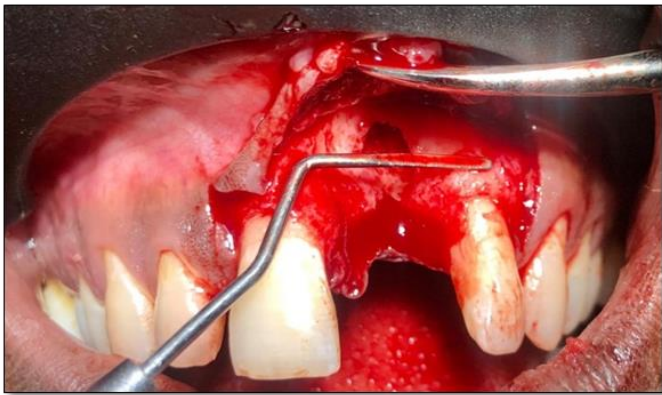

Fig.4: Tissue undermining was performed



Fig. 5: Sticky bone prepared

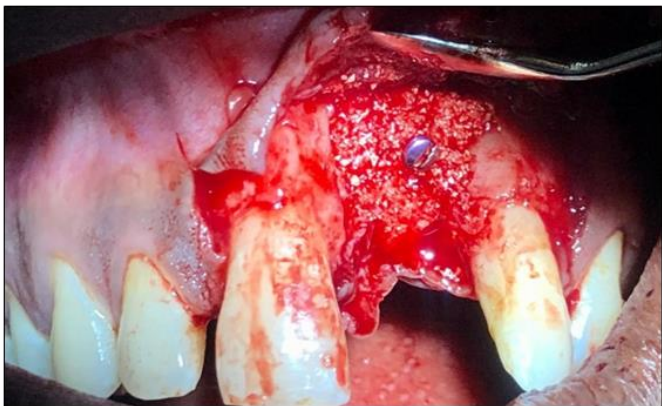

Fig. 6: Sticky bone placed around screw

- Osteon-II bone graft (0.2-0.5mm) was mixed with PRF (platelet rich fibrin) & sticky bone was prepared and adapted at defect site and around the screw, PRF membrane was placed to cover the screw completely.




Fig. 7: PRF Plug Prepared

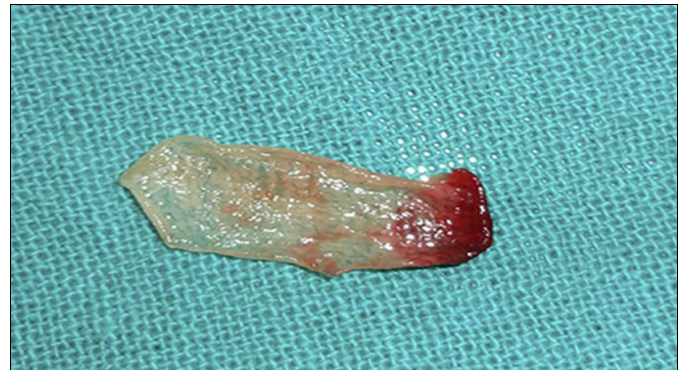

Fig. 8: PRF Membrane

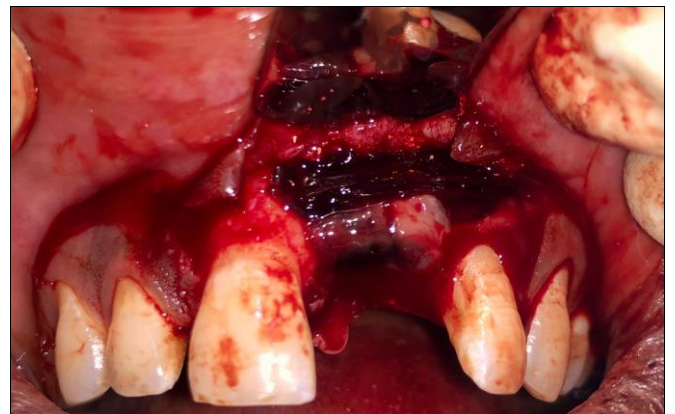

Fig. 9: Sticky Bone + PRF Membrane



Fig. 10: Osteon- II Bone Graft

- Flap were approximated, passive primary closure over entire graft was obtained with 3-0 monocryl interrupted suture.
- Patient was recalled 7 days postoperatively for suture removal
- He has prescribed, analgesics & antibiotics for 5 days & 0.2% chlorhexidine gluconate mouthrinse for 2 weeks.

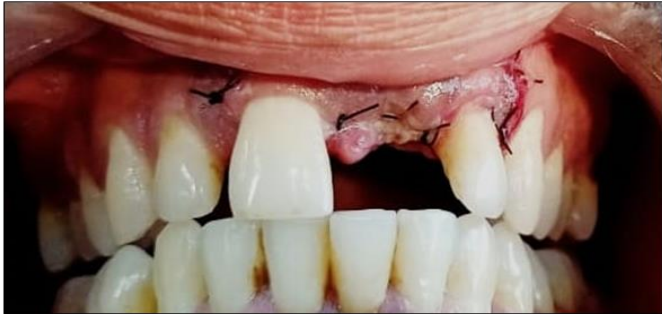

Fig. 11: Suture Placed

Patient was evaluated clinically & radiographically, successful ridge augmentation in vertical & horizontal direction was obtained.

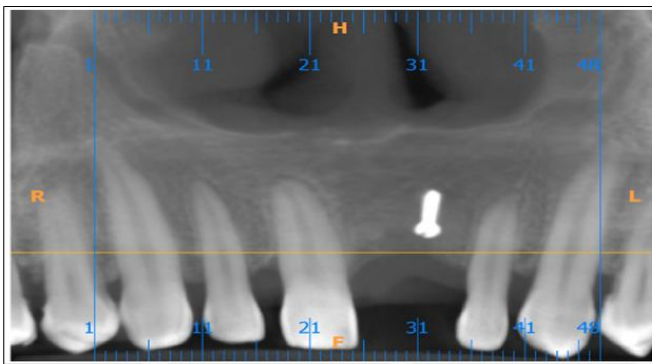


Fig. 12: Post-Operative CBCT after 1 Month

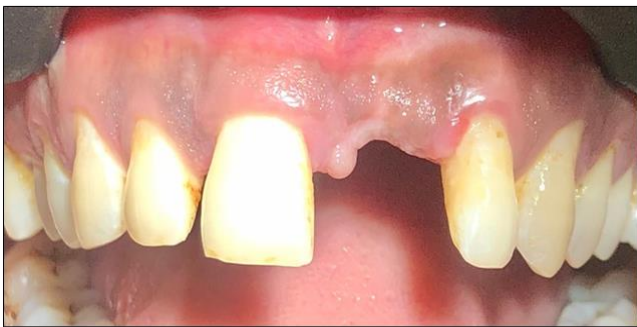

Fig.13: Post-Operative view clinically after 1 month

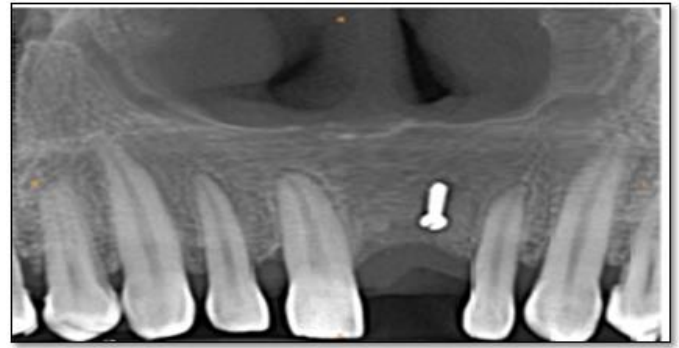

Fig.14: Post-operative CBCT view

Discussion

We found that there was soft tissue deficiency & vertical & horizontal bone loss, so bone augmentation done using tent pole technique, this paper is to describe the evolution of tent pole technique from when the concept was first reported in **2002 by Marx et al.** till the present scenario with its use of bone graft material with this technique for augmentation of bone height.

Fenton, Nish, Carmichael (2006) published a preliminary report on metastatic mandibular retinoblastoma in a child reconstructed with soft tissue matrix expansion grafting, otherwise known as “tent pole graft”. They concluded that soft tissue matrix expansion grafting can be successfully utilised in the reconstruction of ablative defects in paediatric patients also.

Mastin (2007) used cortical “tentpole” grafting technique in severely atrophic alveolar ridge for implant site preparation.

Manfro, Batassini, Bortoluzzi (2008) published a case report regarding severely resorbed mandible treated by soft tissue matrix expansion (tentpole grafts). They reported a 2year follow up case of severely resorbed mandible successfully treated by soft tissue matrix expansion (tent pole) and cranial bone graft with no removable screw retained acrylic resin prosthesis supported by 4 dental implants.

Wannfors, Johansson, Donath (2009) published a case report in which augmentation of the mandible was done

by “tent pole procedure” and implant treatment in a patient with Type III osteogenesis imperfecta. Platelet rich plasma was used to accelerate bone healing. The implant supported metal ceramic restoration was serving well at 1 year and 3 year follow up.

Conclusion

We conclude that, the tent-pole technique is an safe and effective method in the bone regeneration & increasing in vertically & horizontal alveolar ridge dimensions & minimizing postoperative complications, and facilitating subsequent implant placement. Subsequently preventing graft from displacement or physiological resorption.

References

1. De Wijs FL, Cune MS. Immediate labial contour restoration for improved esthetic: a radiographic study on bone splitting in anterior single-tooth replacement. *Int J Oral Maxillofac Implant.* 1997;12:686e696.
2. Gaggl A, Rainer H, Chiari FM. Horizontal distraction of the anterior maxilla in combination with bilateral sinus lift operation preliminary report. *Int J Oral Maxillofac Surg.* 2005;34:37e44.
3. Fenton CC, Nish IA, Carmichael RP, Sandor GK. Metastatic mandibular retinoblastoma in a child reconstructed with soft tissue matrix expansion grafting: a preliminary report. *J Oral Maxillofac Surg.* 2007 Nov;65:2329e2335. PubMed PMID: 17954334.
4. Manfro R, Batassini F, Bortoluzzi MC. Severely resorbed mandible treated by soft tissue matrix expansion (tent pole) grafts: case report. *Implant Dent.* 2008Dec;17:408e413.
5. Le B, Burstein J, Sedghizadeh PP. Cortical tenting grafting technique in the severely atrophic alveolar ridge for implant site preparation. *Implant Dent.* 2008Mar;17:40e50.

6. Wannfors K, Johansson C, Donath K. Augmentation of the mandible via a “tent-pole” procedure and implant treatment in a patient with type III osteogenesis imperfecta: clinical and histologic considerations. *Int J Oral Maxillofac Implants.* 2009 Nov-Dec;24:1144e1148. PubMed PMID: 20162121.
7. Marx RE, Shellenberger T, Wimsatt J, Correa P. Severely resorbed mandible: Predictable reconstruction with soft tissue matrix expansion (tent pole) grafts. *J Oral Maxillofac Surg.* 2002;60(8):878–888.
8. Daga D, Mehrotra D, Mohammad S, Singh G, Natu SM. Tentpole technique for bone regeneration in vertically deficient alveolar ridges: A review. *J Oral Biol Craniofac Res.* 2015;5(2):92–97.