

Denture labelling as an identification tool in forensic medicine- A case report

¹Dr. Yashi Garg, Post graduate student, Department of Prosthodontics, K.D. Dental College & Hospital, Mathura, U.P., India-281121.

²Dr. Rahul Nagrath, Professor, Department of Prosthodontics, K.D. Dental College & Hospital, Mathura, U.P., India-281121.

³Dr. Manesh Lahori, Professor and Head, Department of Prosthodontics, K.D. Dental College & Hospital, Mathura, U.P., India-281121.

Corresponding Author: Dr. Yashi Garg, Post graduate student, Department of Prosthodontics, K.D. Dental College & Hospital, Mathura, U.P., India-281121.

Citation this Article: Dr. Yashi Garg, Dr. Rahul Nagrath, Dr. Manesh Lahori, “Denture labelling as an identification tool in forensic medicine- A case report”, IJMSIR- March - 2022, Vol – 7, Issue - 2, P. No. 70 – 73.

Type of Publication: Case Report

Conflicts of Interest: Nil

Abstract

Denture labelling is gaining popularity in geriatric patients particularly for those staying alone or in old age home, especially the ones suffering from dementia or physical vulnerability. Various methods of denture labelling have been proposed by prosthodontists over the years. Prosthodontist are playing an important role in forensic odontology nowadays. This article highlights a method of denture identification marking wherein a patient’s photograph along with his name and emergency contact number is incorporated within the complete denture.

Keywords: denture labelling, denture marking, personal identification

Introduction

Personal identity is of utmost importance in the society and is also considered a vital part of forensics. Forensic dentistry is a part of dentistry which deals in collection, examination and evaluation of dental evidence and then presenting findings in interest of justice. Denture

marking is an accepted method of identifying a person through their dentures especially during times like road accident, social unrest, natural calamity, war and crimes.[1] It is also advantageous in people with memory disorders. Today Prosthodontists are contributing to forensic dentistry by fabricating prostheses having personal identification markers.

Dr Robert H. Griffiths emphasized on the concept of denture identification.[2] Since then, various methods of denture labelling/marking have been proposed which can be broadly categorized into surface marking and inclusion method. Methods of surface marking includes scribing or engraving letters or numbers, embossing method wherein letters are scratched on cast resulting in embossing on intaglio surface of denture.[3,4] Inclusion methods includes incorporating bar codes, lead foil, electronic microchips, stainless steel metal band, patient’s photograph, radiofrequency tags, laser etched disc and paper strips in prosthesis.[5-8] These materials are incorporated in posterolateral part of palate in

maxillary denture and distolingual flange in mandibular denture.[9]

Case Report

A 78-year-old male patient reported to the department with chief complaint of difficulty in chewing. Oral examination revealed completely edentulous maxillary and mandibular arch. It was planned to fabricate a denture with personal identification features. Technique used was as follow:

1. With written consent of patient his stamp sized photograph along with name and an emergency contact number was printed in an easy-to-read font style of 8-point font size. They were laminated using cellophane sheet to protect its ink from monomer.
2. Denture was fabricated following the standard protocol and it was finished and polished.
3. On the polished surface of distolingual flange of mandibular denture, 5mm wide and 1mm deep slot was made. Laminated emergency contact number was placed in slot prepared and autopolymerising clear acrylic resin was placed in increments. It was then placed in a bowl of warm water and cured for 15 minutes (Figure 1).
4. In the similar way, a slot was prepared on polished surface of posterior part of palate and laminated patient's photograph with name was placed. Clear acrylic resin was placed, placed in warm water and allowed to set (Figure 2).
5. Denture was again polished and delivered to patient (Figure 3).
6. Oral hygiene instructions were given to patient and patient was recalled after one week for follow up.

Discussion

Denture labelling acts as an important identification tool in forensic odontology. American Dental Association encourages fabrication of dentures with denture labelling.

Various methods are available such as scribing or engraving letters or numbers, incorporating bar codes, lead foil, electronic microchips, stainless steel metal band, patient's photograph, radiofrequency tags, laser etched disc and paper strips. [3-8] These denture marking systems helps in identifying a geriatric person especially in cases of mass disasters and accidents.[10]

Kruger-Monson stated requirements for denture labelling: strength of prosthesis must not be compromised, method should be easy and cost effective, system should be efficient, marking should be durable, visible, able to withstand humidity and fire.[11] Technique used in this article fulfills the above-mentioned requirements.

Barcode system and microchip are widely used method but requires a mobile or computer to read the data. In developing countries, method which is relatively easy, inexpensive and identified by all people of society is required. Using patient's photograph and name as denture marker serves this purpose. The identity of person can be easily perceived by layman without anyone's support.[7]

The emergency contact number incorporated in denture is helpful for old patients who cannot reach to their home either due to memory issues, health issues or those met with an accident. Denture labelling should be routinely done especially for geriatric patients and hospitalized patients.

Conclusion

In India, denture labelling is not commonly practiced due to lack of awareness. It is duty of dentist to encourage patient for denture labelling by telling them the benefits of it. This article advocates an easy and inexpensive method of denture labelling which should be routinely used for marking dentures of geriatric patients.

References

1. Stevenson RB. Marking dentures for identification. J Prosthet Dent. 1987 Aug;58(2):255.
2. Mohan J, Kumar CD, Simon P. "Denture marking" as an aid to forensic identification. J Indian Prosthodont Soc. 2012 Sep;12(3):131-6.
3. Reeson MG. A simple and inexpensive inclusion technique for denture identification. J Prosthet Dent. 2001 Oct;86(4):441-2.
4. Matsumura H, Shimoe S. Incorporation of a cast, embossed identification plate into a partial denture framework. J Prosthet Dent. 2002 Aug;88(2):215-7.
5. Mahoorkar S, Jain A. Denture identification using unique identification authority of India barcode. J Forensic Dent Sci. 2013 Jan;5(1):60-3.
6. Kumar S, Banerjee S, Dwivedi H, Gupta T, Banerjee A. Personal identification using complete dentures. Int J Prosthodont Restor Dent 2011; July-Sep; 1:132-135.
7. Anehosur GV, Acharya AB, Nadiger RK. Usefulness of patient photograph as a marker for identifying denture-wearers in India. Gerodontology. 2010 Dec;27(4):272-7.
8. Kareker N, Aras M, Chitre V. A Review on Denture Marking Systems: A Mark in Forensic Dentistry. J Indian Prosthodont Soc. 2014 Dec;14(Suppl 1):4-13.
9. Gujjalapudi M, Anam C, Mamidi P, Saxena A, Kumar G, Rathinam J. The New ID Proof: A Case Report of Denture Labeling. J Orofac Res 2013 Jan-Mar;3(1):63-65.
10. Pathak C, Pawah S, Sikri A, Rao I. Unique Denture Identification System for All Indian Nationals. Contemp Clin Dent. 2018 Jun;9(1):185-188.
11. Patel D, Datta A, Bhise G, Chethan M D, Nandeeshwar D B. Identification of the deceased in

disaster by barcode: Aadhaar-linked complete denture. Int J Forensic Odontol 2019 Jan;4(1):43-6

Figure Legends

Figure 1: Emergency contact number incorporated in denture.

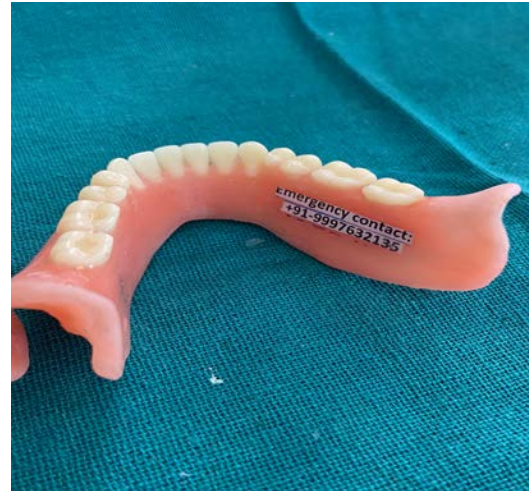

Figure 2: Patient's photograph with name incorporated in denture.

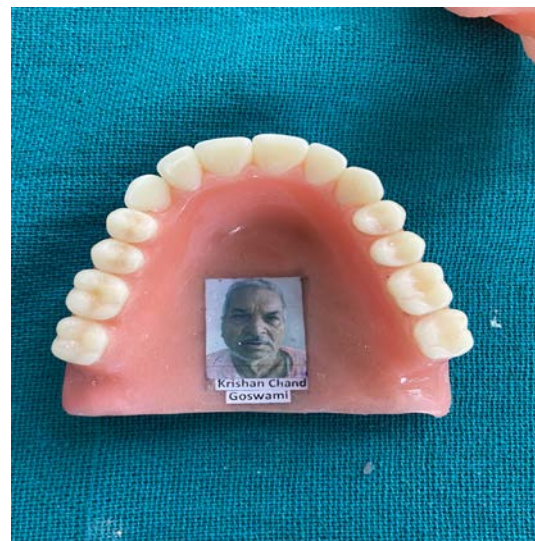


Figure 3: Postoperative view showing denture marking.

