



Autoimmune encephalitis: A case series and review of literature

¹Dr Suhail Ahmad Para, ²Dr Omar Farooq, ³Dr. Javed Chashu, ³Dr. Irfan Shah, ³Dr. Shoaib, ⁴Dr. Shabir, ⁴Dr. Naieem, ⁴Dr. Kiran, ⁴Dr. Himayun, ⁴Dr. Irfan, ⁴Dr. Nasir, ⁴Dr. Danish, ⁴Dr. Naisem, ⁴Dr. Barghavi

¹Registrar, ²Professor, ³Consultants, ⁴PG scholars

Corresponding Author: Prof. (Dr.) Omar Farooq, Professor, Neurologist, Department of Medicine, GMC Srinagar, J&K, India

Citation this Article: Dr Suhail Ahmad Para, Dr Omar Farooq, Dr. Javed Chashu, Dr. Irfan Shah, Dr. Shoaib, Dr. Shabir, Dr. Naieem, Dr. Kiran, Dr. Himayun, Dr. Irfan, Dr. Nasir, Dr. Danish, Dr. Naisem, Dr. Barghavi, “Autoimmune encephalitis: A case series and review of literature”, IJMSIR - March - 2024, Vol – 9, Issue - 2, P. No. 79 – 91.

Type of Publication: Case Report

Conflicts of Interest: Nil

Introduction

Encephalitis (inflammation of the brain parenchyma) is a common medical emergency. Failure to appropriately diagnose the correct aetiology of an encephalitic syndrome can lead to significant morbidity and mortality. Of infectious agents, viruses cause a significant proportion of encephalitis. Herpes simplex encephalitis (HSE) is the most common viral encephalitis with 2000 cases per year in the USA, the majority of cases being HSV-1 infection in the young and elderly.¹ However, non-infectious aetiologies and, more specifically, autoimmune phenomena are being increasingly recognized as causes of encephalitis. A variety of autoimmune causes have now been described including anti-LGI1 encephalitis (previously termed anti-voltage-gated potassium channel “anti-VGKC” antibody encephalitis) and anti-N-methyl-D-aspartic acid receptor (anti-NMDAR) encephalitis.^{2,3,4} It has been recognized that some patients presenting with encephalitis show full recovery after treatment with steroids or immunomodulatory therapy indicating an autoimmune cause even in the absence of confirmatory serology.^{5,6}

Despite growing knowledge of autoimmune encephalitis, this area remains poorly understood. Diagnosis is often considered late or not at all, resulting in poor outcomes. Moreover, recent clinical review articles giving an overview of viral encephalitis omit recognized autoimmune causes such as anti-NMDAR encephalitis in an otherwise comprehensive list of non-infective differential diagnosis.⁷ The intension of this case series is to raise awareness of autoimmune encephalitis, a potentially reversible cause of a common medical emergency. We present three illustrative cases of AE to compare and contrast the variability of presentations, aetiology, management and outcome.

Types of Autoimmune Encephalitis

Auto-antibody	Median age of onset	M: F	Clinical manifestations	Tumor association	Response to therapy
NMDAR	21 (2 months-85 yrs)	1:4	<ul style="list-style-type: none"> • Prominent neuropsychiatric manifestations • Seizures • Movement disorders • Language disorders • Autonomic dysfunction • Central apnea • Coma 	Ovarian teratoma	<ul style="list-style-type: none"> • Almost 53% reported improvement within the first 4 weeks from first-line therapy or tumor removal. • Almost 80% achieved good outcomes in the first 24 months with mRS 0-2. • About 10 % relapse seen within 2 years. Reduced if treated with IT or tumor removal. • 5-7% mortality.
LG1	61 (31-84)	2:1	<ul style="list-style-type: none"> • Limbic encephalitis • Focal seizures • Hyponatremia • Classical fasciobrachial dystonic seizures 	Thymoma, lung, renal, and thyroid cancer	<ul style="list-style-type: none"> • 80% response to IT. • Mild cognitive defect at 2 yrs follow-up. • Relapses are common (35%).
CASPR2	66 (25-77)	9:1	<ul style="list-style-type: none"> • Limbic encephalitis • Morvan syndrome • Peripheral nerve excitability 	Thymoma	<ul style="list-style-type: none"> • Almost 48% had full/good recovery with IT or tumor removal. • About 44% had partial recovery with IT. • About 25% relapses • Case fatality rate 10% after 2 yrs
GABA-a	40 (2.5months-88yrs)	1:1	<ul style="list-style-type: none"> • Limbic encephalitis • Seizures • Refractory status epilepticus 	Thymoma	<ul style="list-style-type: none"> • substantial improvement(86%), although mortality with status epilepticus reported
GABA-b	61 (16-77)	1.5:1	<ul style="list-style-type: none"> • Limbic encephalitis • Seizures 	Small cell lung carcinoma	<ul style="list-style-type: none"> • Neurological response with immunotherapy and cancer treatment (90%)
AMPA	53.1 (14-92)	1:2	<ul style="list-style-type: none"> • Limbic encephalitis 	Thymus, lung, breast, and	<ul style="list-style-type: none"> • Good response to IT

			<ul style="list-style-type: none"> • Confusion • Amnesia • Seizures • Psychiatric complaints 	ovarian cancers	<ul style="list-style-type: none"> • 16% died from complications related to underlying malignancy
DPPX	53 (13-75)	1.6:1	<ul style="list-style-type: none"> • Multifocal encephalitis • Amnesia • Delirium • Myoclonus • Prominent weight loss and diarrhea 	B-cell neoplasm (gastrointestinal lymphoma and CLL)	<ul style="list-style-type: none"> • ~63% responsive to IT
Glycine	50 (1-75)	1:1	<ul style="list-style-type: none"> • Stiff person spectrum syndrome • PERM (progressive encephalitis with rigidity and myoclonus) • Encephalitis 	Thymoma, B - cell lymphoma	<ul style="list-style-type: none"> • Good response to IT, with median mRS =1 at most recent follow-up. • 29% associated with autoimmune disorders (psoriasis, thyroid, diabetes)
MOG	30.5 (15-69)	1:1	<ul style="list-style-type: none"> • optic neuritis • Seizures • Encephalitis 		<ul style="list-style-type: none"> • Good response to IT • Relapses are common.
Neurexin	44 (23-57)	1:2	<ul style="list-style-type: none"> • Prodromal fever • Weight loss • Gastrointestinal symptoms • Confusion • Seizures • Decreased level of consciousness 		<ul style="list-style-type: none"> • Partial response to IT (60%)
IgLON	64 (42-81)	1:1	<ul style="list-style-type: none"> • Sleep disorders, bulbar dysfunction • Gait abnormalities. • HLADRB1*10:01/HLADQB*05:01 alleles in 87%. 		<ul style="list-style-type: none"> • 43% respond better with combination therapy vs. monotherapy (67 vs. 32) • Better with second-line compared to first line. (54 vs. 33)

Case – 1 (Anti-NMDA Antibody Encephalitis)

A 47 year old male with no known comorbidities, presented to casualty with 3 day history of fever and abnormal behaviour. Patient had started with low grade fever which gradually worsened over some hours and was followed by abnormal behaviour in the form of irrelevant talking, abusive language and disorientation. There was no history of weakness of any side of body, history suggestive of cranial nerve palsies or bowel or bladder involvement. Patient's past history was medically insignificant. Patient was admitted and clinical examination revealed a GCS of 14/15 (E4V4M6), pulse of 102 beats/minute, temperature of 101 F. There was no pallor, icterus cyanosis or edema. Respiratory, cardiovascular system and abdominal examination was unremarkable. CNS examination revealed impaired higher mental functions with no apparent cranial nerve palsies. Motor system examination was unremarkable. Planters showed bilateral flexor response. Meningeal signs were present.

Investigations revealed a normal collective blood count, normal KFTs/LFTs/ ABG/ normal spot urine and a normal NCCT head. CSF analysis was done which revealed 110 cells with predominantly lymphocytes (90%) with normal protein and glucose. HSV PCR was negative, so was staining for AFB and fungal elements. CSF ADA was within normal limits. CEMRI brain was done which showed hyperintensity in T2 weighted and FLAIR images in left temporal lobe. Patient was started on Acyclovir in view of lymphocytic pleocytosis of CSF with normal sugar and protein. Patient showed transient mild improvement after receiving Acyclovir but subsequently worsened in terms of his behaviour. A repeat CSF analysis was done in view of patient's worsening symptoms which showed no cells with protein of 96mg/dL and normal glucose. HSV PCR was again

negative, so was the staining for AFB and fungal elements. CSF cultures were sterile. In view of his clinical condition, patient was further investigated in order to rule out autoimmune and limbic encephalitis. Systemic screening by means of CECT chest/abdomen/pelvis was done which was unremarkable apart from mild emphysematous changes in both lung fields. Paraneoplastic panel was also negative while CSF came out to be positive for NMDA antibody. Patient was managed as anti NMDA antibody encephalitis and was started on IV methylprednisolone. He received 5 doses of the drug but did not show much improvement. An alternative therapy with IVIGs was started. After receiving 5 doses of IVIg at a dose of 25g/day (400mg/Kg/day), patient started improving.

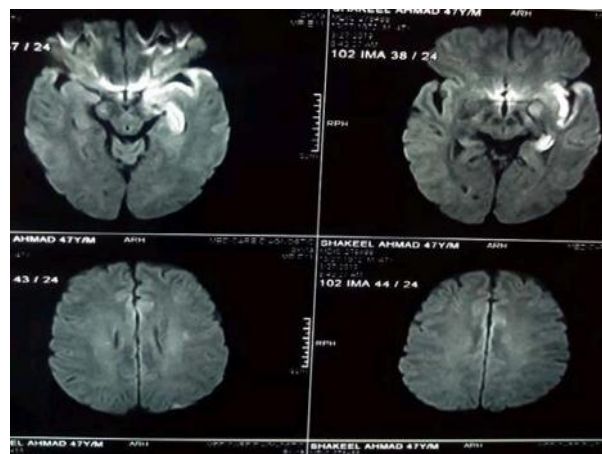


Figure 1

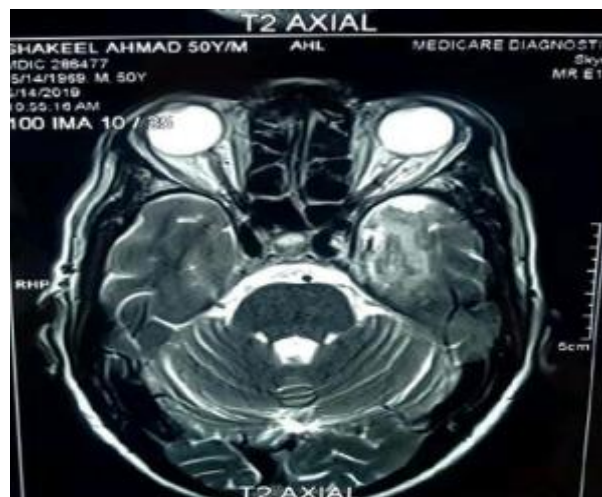


Figure 2

Anti-NMDA receptor encephalitis: a review of Literature

Anti-NMDA receptor encephalitis is the best characterized of the autoimmune encephalitis syndromes and is associated with a predictable set of symptoms that combine to make up a characteristic syndrome.^{8,9}

Clinical features

Many patients present with prodromal headache, fever, or a viral-like process, followed in a few days by a multistage progression of symptoms that include: Prominent psychiatric manifestations (anxiety, agitation, bizarre behavior, hallucinations, delusions, disorganized thinking); isolated psychiatric episodes may rarely occur at initial onset or at relapse¹⁰, insomnia, memory deficits, seizures, decreased level of consciousness, stupor with catatonic features, frequent dyskinesias: orofacial, choreoathetoid movements, dystonia, rigidity, opisthotonic postures, autonomic instability: hyperthermia, fluctuations of blood pressure, tachycardia, bradycardia, cardiac pauses, and sometimes hypoventilation requiring mechanical ventilation, language dysfunction: diminished language output, mutism, echolalia.

Children as young as eight months have been reported with this syndrome¹¹. In children, the symptoms are similar to those of the adults, with prominent early psychiatric symptoms in most patients; dysautonomia and hypoventilation are less frequent and severe. Presenting symptoms usually include acute behavioral change, seizures, language dysfunction, and prominent dyskinesias, including dystonia and chorea.¹² Although rare, approximately 5 percent of patients are >45 years of age.

Diagnosis and differential diagnosis

The disorder should be suspected in adults or children that develop the above clinical symptoms, usually accompanied by:

- Cerebrospinal fluid (CSF) lymphocytic pleocytosis or oligoclonal bands (although basic CSF parameters can be normal initially).
- Electroencephalography (EEG) with infrequent epileptic activity, but frequent slow, disorganized activity that does not correlate with most abnormal movements.
- Brain magnetic resonance imaging (MRI) that is often normal or shows transient fluid-attenuated inversion recovery (FLAIR) or contrast-enhancing abnormalities in cortical (brain, cerebellum) or subcortical (hippocampus, basal ganglia, white matter) regions¹³. While not routinely performed, positron emission tomography (PET) reportedly shows a characteristic increase in the frontal-occipital gradient of cerebral glucose metabolism, which correlates with disease severity.

The diagnosis of anti-NMDA receptor encephalitis is confirmed by the detection of immunoglobulin G (IgG) antibodies to the GluN1 (also known as NR1) subunit of the NMDA receptor in serum or CSF.¹⁴ CSF IgG antibody testing is highly sensitive and specific for anti-NMDA receptor encephalitis; false-positive and negative results may occur when testing only serum. IgM and IgA antibodies against the NMDA receptor, which have been described in some patients with chronic schizophrenia or other chronic neurologic disorders, are nonspecific, do not alter NMDA receptors in vivo, and have no additional value in the diagnosis of NMDA receptor encephalitis. CSF antibodies are always present at the time of presentation; most patients have intrathecal synthesis of antibodies. After treatment or in advanced

stages of the disease, the CSF antibodies usually remain elevated if there is no clinical improvement, while serum antibodies may be substantially decreased by treatments.¹⁵ The titer of CSF antibodies appears to correlate more closely with the clinical outcome than serum titers. The differential diagnosis of this clinical presentation includes primary psychiatric disorders (acute psychosis or schizophrenia), malignant catatonia, neuroleptic malignant syndrome, viral encephalitis¹⁶, and encephalitis lethargica, among others.

Association with ovarian teratoma and other tumors

The detection of an ovarian teratoma is age dependent; approximately 50 percent of female patients older than 18 years have uni- or bilateral ovarian teratomas, while less than 9 percent of girls younger than 14 years have a teratoma.¹⁷ Ovarian teratomas are often revealed by MRI and computed tomography (CT) of the abdomen and pelvis, along with abdominal or transvaginal ultrasound. In male patients, the detection of a tumor is rare. Cases with associated tumors other than ovarian teratoma include testicular germ cell tumor, teratoma of the mediastinum, small cell lung cancer (SCLC), Hodgkin lymphoma, ovarian cystadenofibroma and neuroblastoma. The frequency of underlying tumors in older patients (>45 years) is low, and when present, tumors are more often carcinomas instead of teratomas.

Association with HSVE

Although preceding infections have been suspected to play a role in triggering autoimmune encephalitis, to date this has only been demonstrated for herpes simplex viral encephalitis (HSVE). Studies have shown that approximately 20 to 30 percent of patients who are NMDA receptor antibody negative in serum and CSF at the time of HSVE infection seroconvert to positive NMDA receptor antibodies (or less commonly other antineuronal antibodies) in the setting of relapsing

symptoms not attributable to HSVE relapse.¹⁸ A smaller proportion develop NMDA receptor or other antibodies in the absence of clinical symptoms. Symptoms of anti-NMDA receptor encephalitis in these cases begin at a median of four to six weeks after initial viral infection and may occur in contiguity with or after recovery from the HSVE.¹⁹ In a series of 58 patients with antibody-confirmed autoimmune encephalitis after HSVE (74 percent with NMDA antibodies), the most common symptoms were change of behavior (93 percent), decreased level of consciousness (57 percent), choreoathetosis (47 percent, all in children four years of age or younger), seizures (38 percent), and dysautonomia (27 percent). In most pediatric cases, symptoms have included choreoathetosis and/or orofacial dyskinesias; teenagers and young adults are more likely to develop behavioral and psychiatric symptoms. Prompt diagnosis and treatment with immunotherapy improve symptoms and outcome despite persistence of deficits from the HSVE, especially in older children and adults. In addition to NMDA receptor antibodies, antibodies to gamma amino butyric acid A (GABA-A), dopamine 2 receptor, and unknown neuronal cell-surface antigens have been reported in patients with autoimmune encephalitis after HSVE.²⁰

Treatment and prognosis

Treatment options include immunosuppression and tumor resection when indicated. Progressive neurologic deterioration and death can occur without treatment. However, spontaneous recovery has also been described in a few patients after several months of severe symptoms. In the absence of prospective and randomized data, treatment decisions should be individualized and take into consideration patient age, the presence or absence of a tumor, and symptom severity. Based on observational studies reviewed below and clinical

experience, we suggest initial treatment with intravenous methylprednisolone (e.g., 1 gram daily for five days in an adult) and either intravenous immunoglobulin G (IVIG; e.g., 400 mg/kg per day for five days) or plasma exchange in most patients, in addition to tumor removal when appropriate. It is unknown whether IVIG and plasma exchange have similar efficacy; some clinicians may find IVIG easier to administer in patients with anti-NMDA receptor encephalitis, who may be very young and have severe dyskinesias, agitation, and autonomic instability. If there is no evidence of clinical improvement with initial therapies, we proceed with second-line therapies including rituximab (either 375 mg/m² weekly for four weeks, or 1 g twice two weeks apart), cyclophosphamide (750 mg/m² monthly for four to six months depending on results), or both. An alternative approach to stepwise escalation of immunotherapy is to use rituximab in combination with steroids and IVIG or plasma exchange as initial therapy. As noted above, patients with anti-NMDA receptor encephalitis are at risk for relapse. Relapse occurs in 15 to 24 percent of patients, sometimes after several years. Relapse may occur in the absence of a tumor or in association with an occult or recurrent teratoma. In several series, relapses were more common among those who did not receive immunotherapy with the initial presentation. Relapses are typically treated similarly to the approach in newly diagnosed patients, with a lower threshold to initiate second-line therapies early in the course of the relapse.

Pregnancy and fetal effects

Transplacental transfer of IgG anti-NMDA receptor antibodies has been documented in serum of babies born to mothers with anti-NMDA receptor encephalitis. The effect of these autoantibodies on the fetus is not well described and may be variable. Case reports have

described short-term fetal outcomes ranging from normal to early neonatal death.

Case 2 (Anti Dopamine D-2 receptor antibody encephalitis)

A 43 year old female with underlying hypertension presented with sub-acute onset dysarthria, dysphagia and drooling of saliva of 5 days duration without any history of fever, rash, polyarthralgia, loss of consciousness, seizure, diplopia, facial weakness, numbness, limb weakness bladder/bowel symptoms with examination revealing her to be conscious, comprehending verbal commands but little agitated, producing incomprehensible sounds with bilateral 9th and 10th cranial nerve palsy, generalized rigidity all over, brisk reflexes all over with upgoing plantars and rest of the examination was normal. Investigations revealing normal CBC, KFT, LFT, Lipid Profile, routine urine examination, chest x-ray, ECG. Widal, brucella, vasculitic profile, wilson's profile, TSH, Ft4, Anti TPO. CPK, lactate, iron profile, iPTH, tumour markers, triple serology was normal. USG abdomen/ pelvis/ breasts, USG Doppler neck, CECT chest abdomen pelvis, CT Head, MRA MRV Brain were normal. MRI brain was showing bilateral basal ganglia (caudate and lentiform nuclei) hyperintense signal changes without restricted diffusion or abnormal susceptibility (Figure A, B, C). CSF showing neutrophilic pleocytosis, normal sugar, protein, ADA, Gram Staining, AFB Staining, fungal staining and CBNAAT negative, CSF HSV PCR negative. Paraneoplastic profile, autoimmune profile of CSF was negative except anti D2 receptor antibody.

- Patient was managed with ryles tube feeding, antiparkinsonian drugs in view of parkinsonian features and on the line of autoimmune encephalitis, she was given 5 doses of IV methyl prednisolone 1g/day with no improvement. Patient was then given

IVIG 400mg/kg/day for 5 days and there was dramatic improvement in her symptoms and signs and within 10 days patient was able to take orally.

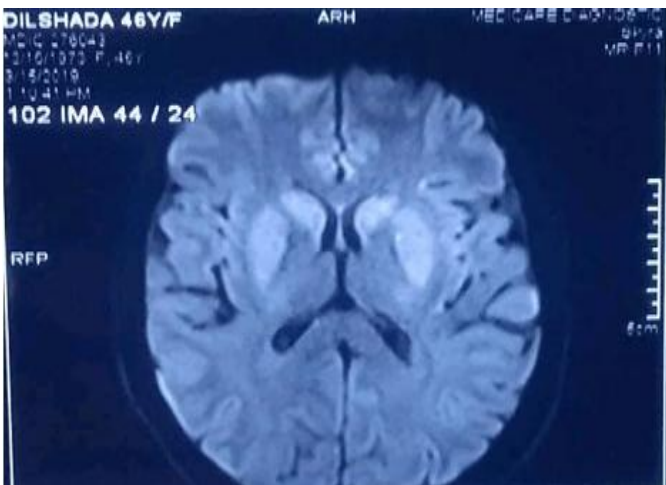


Figure 3

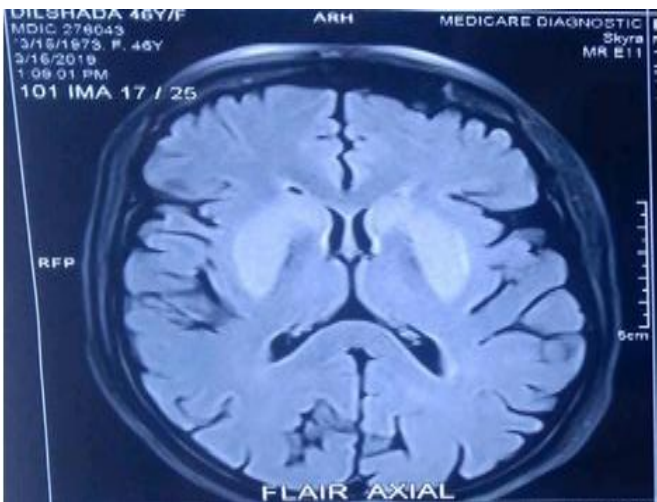


Figure 4

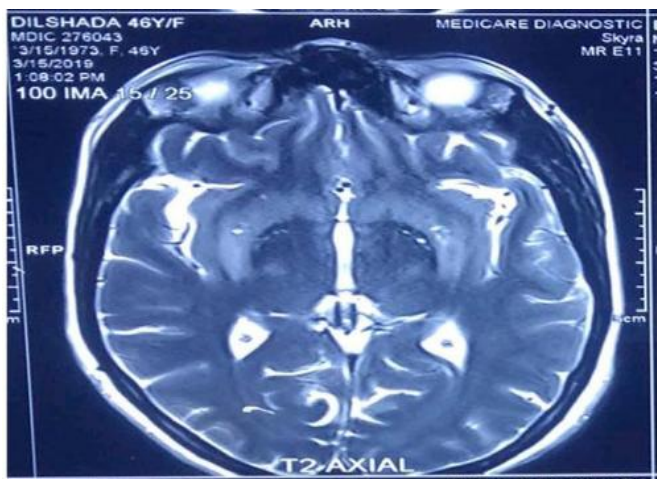

Figure 5

Figure 3,4 & 5 (Diffuse / FLAIR / T2) MRI Brain Images showing bilateral caudate nucleus and putamen hypertensities.

Anti D2 encephalitis: a review of literature

Regional encephalitic syndromes described previously under various names which include basal ganglia encephalitis and encephalitis lethargica specifically affect basal ganglia.²¹ These disorders are proposed to be autoimmune in etiology basal ganglia encephalitis (BEG) patients present with subcortical features which include movement disorders like dystonia, parkinsonism or chorea.²² These patients also present with hypersomnolence and psychiatric features like emotional lability and attention deficit, psychosis and obsessive compulsive disorder. Response to immunotherapy, histopathology of basal ganglia revealing lymphocytic cuffing and inflammatory CSF (lymphocytic pleocytosis and oligoclonal bands) support autoimmune process which targets grey matter neurons.^{21,23} FDG-PET done in these patients mostly demonstrate basal ganglia hypermetabolism. MRI in some of these patients reveals T2 weighted hyperintensity, basal ganglia swelling and sometimes signal change in brainstem with basal ganglia gliosis and atrophy on follow up scan.^{21,24} In view of important role of dopamine as neurotransmitter and its impact on movement and psychiatric disorder, Dale et al. did analysis on dopamine receptor as target for auto antibodies in the patients.²⁴

In humans there are five subtypes of dopamine receptors which are rhodopsin like seven transmembrane G protein coupled receptors, and are divided into 2 groups D1 like group (D1R, D5R) and D2 like group (D2R, D3R, D4R) on the basis of their structural biochemical and pharmacological properties (25,26). Dopamine receptor expression, innervation in humans are prominent in the brain, important in regulation of psychological and

neuromuscular functioning like behavior, learning, working memory, gross and fine motor control.²⁷ Dale et.al in a survey found that out of 17 children with basal ganglia encephalitis 12 were negative for Anti-Nmethyl-D-aspartate receptor (anti-NMDA-R) antibodies but had elevated IgG antibodies to extracellular dopamine 2 receptor (D2R) against 67 pediatric controls which were negative for IgG antibodies to D2R. In D2R positive patients, no binding was demonstrated to dopamine 1,3, or 5 receptors, NMDA-R or dopamine transporter immunolabelling was grossly decreased in D2R knockout brains providing further evidence of the role of D2R as target antigen basal ganglia encephalitis patients diagnosed recently who received early immune therapy have shown complete clinical recovery and a reduction in antibody titres. On the contrary patients diagnosed retrospectively who received only steroids without immunomodulatory therapy had residual psychiatric, neurological symptoms and high titres of antibody. Some patients who persisted with anti D2R have shown subsequent relapse seen in autoimmune encephalitis (unpublished data). These antibodies bind to extracellular domain of D2R but their pathogenicity is yet to be demonstrated further study is needed to evaluate role of antibodies in adults and other disease subtypes.

Case 3 (Anti LGI-1 Antibody Encephalitis)

A 65 year old male with a history of Type 2 Diabetes Mellitus presented with a 6 month history of generalised tonic clinic seizures. At the time he was treated with anti-epileptics and MRI Brain and EEG were normal. The seizures were refractory to treatment and he used to get seizure episode every 10 to 15 days. From 1 month patient developed rapidly progressive dementia and psychiatric disturbances. In view of non-responsive seizures despite on maximal anti-epileptic treatment and

rapidly progressive cognitive impairment patient was admitted in our department.

On clinical examination patient had a GCS of 14/15 (E4V4M6), pulse of 80 beats/ minute, temperature of 98.6F. There was no pallor, icterus, cyanosis or edema. Respiratory, cardiovascular system and abdominal examination was unremarkable. CNS examination revealed impaired higher mental functions (MMSC 20) with no apparent cranial nerve palsies. Motor system examination was unremarkable. Planters showed bilateral flexor response. Meningeal signs were absent. Investigations revealed a normal collective blood count, normal CBC/KFTs/LFTs/ Electrolytes/ABG/ normal spot urine and a normal ECG and Chest X-ray. CSF analysis was done which revealed normal cell count with slightly higher protein (77.6) and glucose of 318. CSF viral panel, TB and fungal profile was negative. CSF VDRL was also negative. CEMRI brain (Figure A) and EEG were also normal.

In view of his clinical condition, patient was further investigated in order to rule out autoimmune and paraneoplastic encephalitis. Systemic screening by means of CECT chest/abdomen/pelvis, Tumour markers and PET Scan was done which was unremarkable. Paraneoplastic panel was negative while CSF and serum came out to be positive for anti LGI-1 antibody. Patient was managed as anti LGI-1 antibody encephalitis and was started on IV methylprednisolone. He received 5 doses of the drug followed by oral steroids which were tapered gradually. Patient is now seizure free from last 2 and a half months and his higher mental functions are normal now (MMSC 29).

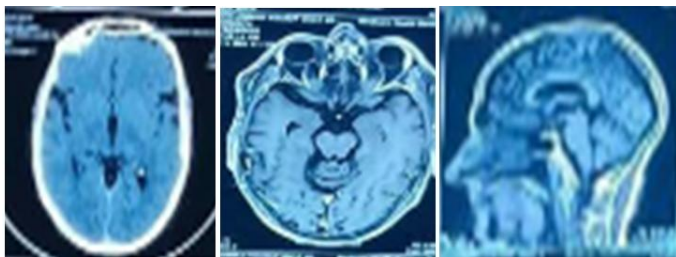


Figure 6: Showing unremarkable MRI study

Anti LGI-1 Encephalitis: A Review Of Literature

LGI-1 antibody encephalitis is autoimmune encephalitis involving autoantibodies of LGI-1 protein, which is secreted from the presynaptic terminal in the hippocampus or neocortex. This antibody triggers epileptiform activity in the hippocampus.²⁸ Faciobrachial dystonia is specifically related to LGI-1 protein expression in the basal ganglia.²⁹ Accordingly, an autoimmune disorder with antibodies against LGI-1 protein may cause limbic encephalitis. LGI-1 antibody encephalitis is predominant in males, accounting for 60%-70% of cases, and has been reported at many adult ages, with a median age of 60 years, in a range of 31-84 years.³⁰ The incidence is as rare as 0.83/million/year³¹, although this might be an underestimation. Of cases, 5%-10% showed an association with thymoma.³² According to Jang et al.³³, 75% of patients diagnosed with LGI-1 antibody encephalitis manifested psychiatric symptoms. Among the Korean case reports, only one reported psychiatric symptom as the initial manifestation of LGI-1 antibody encephalitis.³⁴

Seizure and cognitive disorder are the key symptoms of LGI-1 antibody encephalitis, and faciobrachial dystonic seizure (FBDS) involving the ipsilateral face and limb is typical.³⁵ FBDS (47%) and other subtle focal seizures (66%, autonomic or dyscognitive) often occur before onset of memory disturbance. Tonic-clonic seizures (63%) and FBDS developed later and not as initial symptoms in 25% of patients. The most common

presentation of cognitive impairment in LGI-1 antibody encephalitis is short-term memory impairment. Spatial disorientation, sleep disorders, and autonomic dysfunctions also can occur. Although neurologic symptoms are more characteristic than psychotic symptoms in LGI-1 antibody encephalitis, hallucinations, emotional changes, and depressed mood can be present.³⁶

In LGI-1 antibody encephalitis, hyponatremia is a very common (70%) manifestation in serum study. The CSF test shows an abnormality in up to 25% of patients, often mild pleocytosis with elevated protein. In the EEG study, an abnormal pattern is shown in 50% of cases, 30% as epileptiform abnormality, and 20% as focal swelling. Abnormal brain MRI pattern is seen in up to 75% of patients, with 40% showing increased signal or swelling in the medial temporal lobes. A unilateral pattern is more common than a bilateral pattern [37]. Brain MRIs which were initially normal, had developed hippocampal atrophy or sclerosis later, suggesting that hippocampal inflammation was present but was not detectable by routine MRI in the acute phase.³⁸ Additionally, around 90% of LGI1 antibody encephalitis patients show human leukocyte antigen HLA DRB1.³⁹

As first-line treatment, high-dose methylprednisolone, IVIG, and plasma exchange can be considered. Typical second-line therapy is mycophenolate, azathioprine, rituximab, and cyclophosphamide. Third-line or experimental therapies include bortezomib and tocilizumab. Since >90% of patients with LGI1-antibodies carry the HLA-DRB1*07:01 allele, T-cell-directed therapies might be an option in the future, as generation of antibody secreting cells and memory B cells occurs through engagement of HLA with T cell receptor.^{40,41} Although ascertainment bias should be considered, 1/3 of patients fully recovered, 1/3 were functionally independent but unable to work, and 1/3

were severely disabled or dead within 2 years; relapse occurred in 20%–30% of cases and was associated with poor outcomes. Most central nervous system (CNS) infections including meningitis or encephalitis are accompanied by infectious illness signs such as high fever, chills, and sudden neurological symptoms. Therefore, it is difficult to suspect CNS infection in patients without infectious illness. Here, we report a patient who was diagnosed with LGI-1 antibody encephalitis showing seizures, cognitive impairment and psychiatric symptoms as an initial clinical presentation and absence of hyponatremia. We present this case to demonstrate symptomatic progression of LGI-1 antibody encephalitis and to facilitate the diagnosis of LGI-1 antibody encephalitis with increased awareness.

Conclusion

Despite the fact that AE can manifest similarly to other encephalitic processes, such as those resulting from an infectious aetiology, the instances discussed show that conditions like anti-NMDAR, anti-LGI1, and other AE can have certain unique distinguishing traits. Whether practicing general medicine, neurology, or infectious diseases, the doctor caring for encephalitic patients whose aetiology is unknown needs to be on the lookout for potential AE diagnoses. In the present study, all patients had excellent responses to treatment further supports the urgency with which AE should be considered, looked into, and acknowledged.

References

1. Whitley RJ. Viral encephalitis. *N Engl J Med*, 1990; 323: 242-50.
2. Dalmau J, Gleichman AJ, Hughes EG, Rossi JE, Peng X, Lai M, et al. Anti-NMDA-receptor encephalitis: case series and analysis of the effects of antibodies, *Lancet Neurol*, 2008; 7: 1091-8.

3. Anderson NE, Barber PA. Limbic Encephalitis – a review, *J Clin Neurosci*, 2008; 15: 961-71.
4. Florance NR, Davis RL, Lam C, Szperka C, Zhou L, Ahmad S, et al. Anti-NMDA-receptor encephalitis in children and adolescents, *Ann Neurol*, 2009; 66: 11-18.
5. Urbach H, Soeder BM, Jeub M, Klockgether T, Meyer B, Bien CG, et al. Serial MRI of limbic encephalitis, *Diag Neurorad*, 2006; 48: 380-6.
6. Bataller L, KleopaKL, Wu GF, Rossi JE, Rosenfeld MR, Dalmau J. Autoimmune limbic encephalitis in 39 patients: immunophenotypes and outcomes, *J Neurol Neurosurg Psychiatry*, 2007; 78: 381-5.
7. Solomon T, Hart IJ, Beeching NJ. Viral encephalitis: a clinician's guide, *Pract Neurol*, 2007; 7: 288-305.
8. Dalmau J, Tuzun E, Wu HY, et al. Paraneoplastic anti-N-methyl-D-aspartate receptor encephalitis associated with ovarian teratoma. *Ann Neurol* 2007; 61: 25.
9. Dalmau J, Gleichman AJ, Hughes EG, et al. Anti-NMDA-receptor encephalitis: case series and analysis of the effects of antibodies. *Lancet Neurol* 2008; 7: 1091.
10. Kayser MS, Titulaer MJ, Gresa-Arribas N, Dalmau J. Frequency and characteristics of isolated psychiatric episodes in anti-N methyl-d-aspartate receptor encephalitis. *JAMA Neurol* 2013; 70: 1133.
11. Luca N, Daengsuwan T, Dalmau J, et al. Anti-N-methyl-D-aspartate receptor encephalitis: a newly recognized inflammatory brain disease in children. *Arthritis Rheum* 2011; 63: 2516.
12. Wright S, Hacohen Y, Jacobson L, et al. N-methyl-D-aspartate receptor antibody mediated neurological disease: results of a UK-based surveillance study in children. *Arch Dis Child* 2015; 100: 521.

13. Florance NR, Davis RL, Lam C, et al. Anti-N-methyl-D-aspartate receptor (NMDAR) encephalitis in children and adolescents. *Ann Neurol* 2009; 66: 11.
14. Prüss H, Dalmau J, Harms L, et al. Retrospective analysis of NMDA receptor antibodies in encephalitis of unknown origin. *Neurology* 2010; 75:1735.
15. Seki M, Suzuki S, Iizuka T, Shimizu T, Nihei Y, Suzuki N, Dalmau J. Neurological response to early removal of ovarian teratoma in anti-NMDAR encephalitis. *J Neurol Neurosurg Psychiatry*. 2008 Mar;79(3):324-6.
16. Gable MS, Gavali S, Radner A, et al. Anti-NMDA receptor encephalitis: report of ten cases and comparison with viral encephalitis. *Eur J Clin Microbiol Infect Dis* 2009; 28: 14-21.
17. Titulaer MJ, McCracken L, Gabilondo I, et al. Treatment and prognostic factors for long-term outcome in patients with anti-NMDA receptor encephalitis: an observational cohort study. *Lancet Neurol* 2013; 12: 15-7.
18. Leypoldt F, Titulaer MJ, Aguilar E, Walther J, Bönstrup M, Havemeister S et al. Herpes simplex virus-1 encephalitis can trigger anti-NMDA receptor encephalitis: case report. *Neurology*. 2013 Oct 29;81(18):1637-9.
19. Armangue T, Moris G, Cantarín-Extremera V, Conde CE, Rostasy K, Erro ME et al. Autoimmune post-herpes simplex encephalitis of adults and teenagers. *Neurology*. 2015 Nov 17;85(20):1736-43.
20. Armangue T, Leypoldt F, Málaga I, Raspall-Chaure M, Marti I, Nichter C et al. Herpes simplex virus encephalitis is a trigger of brain autoimmunity. *Ann Neurol*. 2014 Feb;75(2):317-23.
21. Dale RC, Church AJ, Surtees RA, et al. Encephalitis lethargica syndrome: 20 new cases and evidence of basal ganglia autoimmunity. *Brain* 2004;127: 21–33.
22. Dale RC, Irani SR, Brilot F, et al. N-methyl-D-aspartate receptor antibodies in pediatric dyskinetic encephalitis lethargica. *Ann Neurol*2009;66:704–9.
23. Lopez-AlberolaR, Georgiou M, Sfakianakis GN, et al. Contemporary encephalitis lethargica: phenotype, laboratory findings and treatment outcomes. *J Neurol* 2009; 256: 396–404.
24. Dale RC, Merheb V, Pillai S, et al. Antibodies to surface dopamine-2 receptor I autoimmune movement and psychiatric disorders. *Brain* 2012;135:3453–68.
25. Andersen PH, Gingrich JA, Bates MD, Dearth A, Falardeau P, Senogles SE, Caron MG. Dopamine receptor subtypes: beyond the D1/D2 classification. *Trends Pharmacol Sci* 1990;11:231–6.
26. Beaulieu JM, Gainetdinov RR. The physiology, signaling, and pharmacology of dopamine receptors. *Pharmacol Rev* 2011; 63: 182–7.
27. Dale RC, Merheb V, Pillai S, Wang D, Cantrill L, Murphy TK et al. Antibodies to surface dopamine-2 receptor in autoimmune movement and psychiatric disorders. *Brain*. 2012 Nov;135(Pt 11):3453-68.
28. Lalic T, Pettingill P, Vincent A, Capogna M. Human limbic encephalitis serum enhances hippocampal mossy fiber-CA3 pyramidal cell synaptic transmission. *Epilepsia* 2011;52:121–31.
29. Irani SR, Alexander S, Waters P, et al. Antibodies to Kv1 potassium channel-complex proteins leucine-rich, glioma inactivated 1 protein and contactin-associated protein-2 in limbic encephalitis, Morvan’s syndrome and acquired neuromyotonia. *Brain* 2010; 133: 2734–48.

30. van Sonderen A, Schreurs MW, Wirtz PW, Sillevius Smitt PA, Titulaer MJ. From VGKC to LGI1 and Caspr2 encephalitis: The evolution of a disease entity over time. *Autoimmun Rev.* 2016 Oct;15(10):970-4.
31. van Sonderen A, Thijs RD, Coenders EC, et al. Anti-LGI1 encephalitis: clinical syndrome and long-term follow-up. *Neurology* 2016;87: 1449–56.
32. Endres D, Leypoldt F, Bechter K, et al. Autoimmune encephalitis as a differential diagnosis of schizophreniform psychosis: clinical symptomatology, pathophysiology, diagnostic approach, and therapeutic considerations. *Eur Arch Psychiatry Clin Neurosci* 2020;270:803–18.
33. Jang Y, Lee ST, Lim JA, Kim TJ, Jun JS, Moon J, Sunwoo JS, Jung KH, Park KI, Jung KY, Kim M, Lee SK, Chu K. Psychiatric symptoms delay the diagnosis of anti-LGI1 encephalitis. *J Neuroimmunol.* 2018 Apr 15;317:8-14.
34. Kim ES, Lee HJ, Jeon SW, Cho SJ. Anti-LGI1 antibody encephalitis. *Korean J Biol Psychiatry* 2020;27:112–116.
35. Li W, Wu S, Meng Q, et al. Clinical characteristics and short-term prognosis of LGI1 antibody encephalitis: a retrospective case study. *BMC Neurol* 2018;18:96.
36. Herken J, Prüss H. Red flags: clinical signs for identifying autoimmune encephalitis in psychiatric patients. *Front Psychiatry* 2017;8:25.
37. Uy CE, Binks S, Irani SR. Autoimmune encephalitis: clinical spectrum and management. *Pract Neurol* 2021;21:412–423.
38. Finke C, Prüss H, Heine J, et al. Evaluation of cognitive deficits and structural hippocampal damage in encephalitis with leucine-rich, glioma-inactivated 1 antibodies. *JAMA Neurol* 2017;74:50–59.
39. Kim TJ, Lee ST, Moon J, et al. Anti-LGI1 encephalitis is associated with unique HLA subtypes. *Ann Neurol* 2017;81:183–192.
40. Binks S, Varley J, Lee W, et al. Distinct HLA associations of LGI1 and CASPR2-antibody diseases. *Brain* 2018;141:2263-71.
41. Ellebedy AH, Jackson KJ, Kissick HT, Nakaya HI, Davis CW, Roskin KM et al. Defining antigen-specific plasmablast and memory B cell subsets in human blood after viral infection or vaccination. *Nat Immunol.* 2016 Oct;17(10):1226-34.