

Tubercular pyomyositis: A case report

¹Dr.Mudasir Ahmad Dar, PG, Government Medical College and SSH, Srinagar.

²Dr.Omar Farooq, Consultants, Government Medical College and SSH, Srinagar.

³Dr.Irfan Shah, Consultants, Government Medical College and SSH, Srinagar.

⁴Dr.Javaid Chachoo, Consultants, Government Medical College and SSH, Srinagar.

⁵Dr.Shoiab Yousuf, Consultants, Government Medical College and SSH, Srinagar.

⁶Dr.Khushboo, Registrars, Government Medical College and SSH, Srinagar.

⁷Dr.IfraUrooj, Registrars, Government Medical College and SSH, Srinagar.

⁸DrShabir, PG, Government Medical College and SSH, Srinagar.

⁹Dr.Naiem, PG, Government Medical College and SSH, Srinagar.

¹⁰Dr.Hemayoun, PG, Government Medical College and SSH, Srinagar.

¹¹Dr.Kiran, PG, Government Medical College and SSH, Srinagar.

¹²Dr.Bhargavi, PG, Government Medical College and SSH, Srinagar.

¹³Dr.Nasir, PG, Government Medical College and SSH, Srinagar.

¹⁴Dr.Naisam, PG, Government Medical College and SSH, Srinagar.

¹⁵Dr.Danish, PG, Government Medical College and SSH, Srinagar.

¹⁶Dr.Irfan, PG, Government Medical College and SSH, Srinagar.

Corresponding Author: Dr. Omar Farooq, Professor, Neurologist, Department of medicine, Government Medical College and SSH Srinagar.

Citation this Article: Dr. Mudasir Ahmad Dar, Dr. Omar Farooq, Dr. Irfan Shah, Dr. Javaid Chachoo, Dr. Shoiab Yousuf, Dr. Khushboo, Dr. Ifra Urooj, Dr Shabir, Dr. Naiem, Dr. Hemayoun, Dr. Kiran, Dr. Bhargavi, Dr. Nasir, Dr. Naisam, Dr. Danish, Dr. Irfan, “Tubercular pyomyositis: A case report”, IJMSIR- November - 2023, Vol – 8, Issue - 6, P. No. 38 – 41.

Type of Publication: Case Report

Conflicts of Interest: Nil

Abstract

A 60-year-old female with a 2-year history of polymyositis, presented with 1 month history of lower limb pain, worsening of weakness and fever. CECT chest, abdomen and pelvis was suggestive of multiple collections at bilateral pyriforms, paraspinal muscles, bilateral gluteus Medius and minimums and bilateral thighs. The collections were aspirated and was sent to microbiology for culture, AFB, gram staining and

CBNAAT. The aspirate showed acid fast bacilli on smear and CBNAAT was positive. Diagnosis of tubercular pyomyositis was made and patient was put on ATT.

Keywords: CBNAAT, AFB, CECT.

Introduction

Tuberculosis became known in the 19th century when it decimated hundreds of people around the world. From the mid-twentieth century, there was a marked reduction in the incidence and mortality related to TB, already

observed at that time in developed countries, mainly due to the improvement in the living conditions of populations and in health care (1)

In the early 1980s, we witnessed a global upsurge of TB and, since 2015, it is considered a re-emerging disease (1). Its most common form of manifestation is pulmonary and about 20% of diagnosed cases are extra pulmonary forms. Tubercular pyomyositis is one of the extra pulmonary presentations, rarely described in the medical literature and its pathology is still uncertain (2-4). We report here a case of 56-year-old female who is known case of polymyositis on azathioprine and prednisolone, who had tubercular pyomyositis at multiple locations.

Case presentation

The patient is a 60-year-old female with a 2-year history of polymyositis. She presented with 1 month history of lower limb pain, worsening of weakness and fever. She visited various hospitals multiple times but because of her underlying illness she was discharged home multiple times after receiving tramadol infusion. Due to progression of her illness despite treatment she was admitted in general medicine for further evaluation.

Her past medical history included polymyositis for which she was on prednisolone 30mg OD and azathioprine 50 mg BD. Other medication included pregabalin, nortriptyline's was a nonsmoker. She was a housewife resides with her children's in Qazigund kulgam Kashmir.

On physical examination, the patient had a temperature of 100-degree Fahrenheit, BP-110/70, pulse-80 b/m, SPO2-96% on ambient air. She had toxic look and had severe pain. Her pupil was normal. Extraocular movements were full with no cranial nerve palsy. In her left and right axilla she had fistula without any ooze. Her chest, abdomen and CVS were normal. She had lower

limb edema extending from groin to the foot. Power in upper and lower limb were 5/5 and 4/5 respectively.

Investigations

Laboratory investigations revealed anemia (Hb-7), thrombocytopenia (platelet-69k), hypoalbuminemia (alb-2.1), hypercalcemia (calcium-10.9), ESR- 120, CRP-214, CPK-204. IPTH and vit- D 25 were lower than normal. USG neck and axilla was normal. CECT chest, abdomen and pelvis was suggestive of multiple collections at bilateral psoas, paraspinal muscles, bilateral gluteus Medius and minimus and bilateral thighs (fig.1). Patient received empirical antibiotics in the form of meropenem, vancomycin and tigecycline but she did not improve. Collections were aspirated and sent to microbiology for culture, AFB, gram staining and CBNAAT (fig.2). The aspirate showed acid fast bacilli on smear. CBNAAT was positive and quadruple anti tubercular therapy was initiated with isoniazid, rifampicin, pyrazinamide and ethambutol.

After few days of anti tubercular therapy patient developed jaundice and investigations were suggestive of hyperbilirubinemia (bilirubin-1.5) and elevated alkaline phosphatase. Treatment was not stopped and patient was planned for MRCP. However, due to disseminated tuberculosis patient developed hypotension with SBP in the 70s. She was started on vasopressors but unfortunately, she did not improve and died.

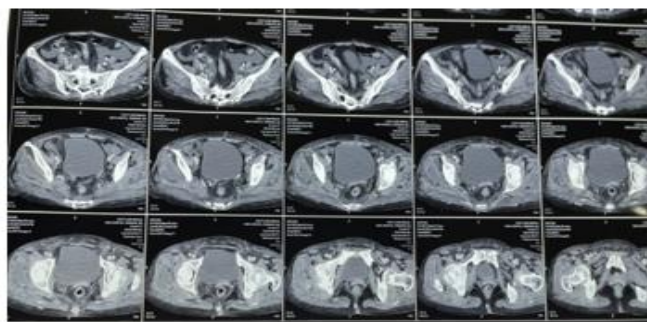
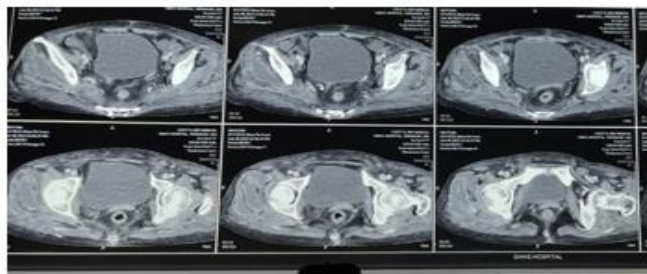


Fig.1: CECT chest/ABD/pelvis




Fig.2: Auromine rhodamine showing AFB

Discussion

Pyomyositis is a purulent infection of muscle that is generally the result of hematogenous spread [5]. Typically, the infection is known to occur in the tropics in otherwise healthy individuals with no comorbidities. Those affected in more temperate regions tend to have severe underlying comorbidities or are immunocompromised in some way [6].

The most common organisms implicated in pyomyositis include staphylococcus aureus as well as increasingly, MRSA. Group A streptococci are also common with

gram-negative bacilli and pneumococci, with non-group A streptococci occurring less often [6]. There have also been instances of mycobacterial induced pyomyositis [7]. Typical presentation of pyomyositis involve fever and muscle pain more in lower extremities [6]. The infection usually progresses in three stages. Stage-1 is characterized by fever, muscle pain and swelling. Since this is an early stage, an abscess may not yet be apparent and very few patients present at this stage. Stage II is where most patients present and occur 2-3 weeks after initial symptoms and is characterized by fever, muscle tenderness and leukocytosis. Aspiration of the area will yield purulent material. Finally, stage III is the most most severe and is accompanied by systemic toxicity. As a result, patient can develop complications of bacteremia [8]. One study showed a mortality rate that reached 10% [9].

Diagnosis is typically made by radiography, predominantly by CT and culture [10]. MRI may also be helpful, especially in tuberculous pyomyositis [11,12]. Because pyomyositis arises from hematologic spread, cultures are extremely useful for determining appropriate antibiotic use [4,5].

Treatment is dependent on the stage of the disease with stage 1 able to be treated by antibiotics. Stage 2-3 require both drainage as well as antibiotic treatment. Drainage is typically CT guided, but in extensive disease, surgical intervention may be needed [8].

Initial empiric antibiotic therapy is generally directed against staphylococci and typically includes MRSA coverage in those who have previous infections, risk factors, or systemic toxicity. If an individual is immunocompromised, antibiotic coverage should be broad, covering gram positive and negative as well as anaerobic organisms [6,8]. For suspected mycobacterial disease, treatment is the same as pulmonary tuberculosis.

Duration of treatment is variable depending on the complications and the organism involved, with mycobacteria requiring longer treatment courses [13].

References

1. Ministry of Health (BR). Health Surveillance Department. Department of Epidemiological Surveillance. Manual of Recommendations for the Control of Tuberculosis in Brazil. Brasilia: Ministry of Health. 2019.
2. Simon SP, Fodor D, Valasciuc R, et al. A rare case of primary tuberculous pyomyositis. Case Report. Med Ultrason. 2011; 13(3): 245-8
3. Yao DC, Sartoris DJ. Musculoskeletal-Altuberculosis. Radiol Clin North Am. 1995; 33: 679-89.
4. Batra S, AbNaell M, Barwick C, et al. Tuberculous pyomyositis of the thigh masquerading as malignancy with concomitant tuberculous flexor tenosynovitis and dactylitis of the hand. Singapore Med J. 2007; 48(11): 1042-6.
5. D. L. Stevens, A. L. Bisno, H. F. Chambers et al., "Practice guidelines for the diagnosis and management of skin and soft tissue infections," *Clinical Infectious Diseases*, vol. 41, no. 10, pp. 1373–1406, 2005.
6. N. F. Crum, "Bacterial pyomyositis in the United States," *American Journal of Medicine*, vol. 117, no. 6, pp. 420–428, 2004.
7. J. Y. Wang, L. N. Lee, P. R. Hsueh et al., "Tuberculous myositis: a rare but existing clinical entity," *Rheumatology*, vol. 42, no. 7, pp. 836–840, 2003.
8. L. Chukwuma Chiedozi, "Pyomyositis. Review of 205 cases in 112 patients," *American Journal of Surgery*, vol. 137, no. 2, pp. 255–259, 1979.
9. A. Sharma, S. Kumar, A. Wanchu et al., "Clinical characteristics and predictors of mortality in 67 patients with primary pyomyositis: a study from North India," *Clinical Rheumatology*, vol. 29, no. 1, pp. 45–51, 2010
10. D.W. Struk, P. L. Munk, M. J. Lee, S.G. F. Ho, and D. F. Worsley, "Imaging of soft tissue infections," *Radiologic Clinics of North America*, vol. 39, no. 2, pp. 277–303, 2001.
11. R. Soler, E. Rodríguez, C. Remuñán, and M. Santos, "MRI of musculoskeletal extraspinal tuberculosis," *Journal of Computer Assisted Tomography*, vol. 25, no. 2, pp. 177–183, 2001.
12. J. Y. Kim, Y. H. Park, K. H. Choi, S. H. Park, and H. Y. Lee, "MRI of tuberculous pyomyositis," *Journal of Computer Assisted Tomography*, vol. 23, no. 3, pp. 454–457, 1999.
13. J. B. Bass Jr., L. S. Faren, P. C. Hopewell, and R. F. Jacobs, "Treatment of tuberculosis and tuberculosis infection in adults and children," *American Review of Respiratory Disease*, vol. 134, no. 2, pp. 355–363, 1986.