

**Functional outcome of shaft of humerus fracture with radial nerve palsy treated with open reduction and internal fixation with plating.**

<sup>1</sup>Chintamani Keluskar, Resident doctor, Department of Orthopaedics, Dr. Vithal Rao Vikhe Patil Foundation's Medical College, Ahmednagar.

<sup>2</sup>Deepak Naikwade, Professor and Head of department, Department of Orthopaedics, Dr. Vithal Rao Vikhe Patil Foundation's Medical College, Ahmednagar.

<sup>3</sup>Paresh Pawar, Resident doctor, Department of Orthopedics, Dr. Vithal Rao Vikhe Patil Foundation's, Medical College, Ahmednagar.

**Corresponding Author:** Chintamani Keluskar, Resident doctor, Department of Orthopaedics, Dr. Vithal Rao Vikhe Patil Foundation's Medical College, Ahmednagar.

**Citation this Article:** Chintamani Keluskar, Deepak Naikwade, Paresh Pawar, "Functional outcome of shaft of humerus fracture with radial nerve palsy treated with open reduction and internal fixation with plating", IJMSIR- September - 2023, Vol – 8, Issue - 5, P. No. 190 – 199.

**Type of Publication:** Original Research Article

**Conflicts of Interest:** Nil

**Abstract**

**Aims and objective:** Study the functional outcome of shaft of humerus fracture with radial nerve palsy treated with open reduction and internal fixation with plating. To assess the influence of injury mechanism, fracture type and type of surgical treatment on time to onset of nerve recovery and time to full nerve recovery in patients with humeral shaft fractures and concomitant primary radial nerve palsy.

**Material and methods:** A descriptive study was held at a medical college and tertiary healthcare center from December 2019 to December 2021. Total 30 of patients were included in this study after satisfying inclusion and exclusion criteria.

**Result:** The outcome of radial nerve palsy was not found to be related to age group, sex, side, mechanism of injury, intra-operative condition of nerve, method of

treatment of fracture and time of exploration of radial nerve.

**Conclusion:** Open reduction and internal fixation of humeral shaft fracture gives good results. It provides greater patient comfort and is a good alternative to conservative treatment, as unnecessary avoidance of open reduction and internal fixation in fear of iatrogenic radial nerve palsy, prolongs limb rehabilitation and unemployment of the patients.

**Keywords:** SOTF = Side of Humerus fracture, TOS = Time of surgery, MTR = Mean time of radiation, TU = Time of union(weeks), FO = Outcome

**Introduction**

Fractures of shaft of the humerus account for 3–5% of all fractures.<sup>1</sup> They generally occur as an outcome of direct trauma. It can also occur with high rotating force activity, such as arm wrestling or baseball. The radial nerve

commonly endangered by humerus fractures in the part of middle or distal shaft.

There are many controversies in the literature about management. If the fracture is closed and not displaced, conservative treatment is appropriate; however, if the fracture is closed and displaced, fixation is recommended. Internal or external fixation is possible, however open reduction and plating are well-known methods of therapy. Traditional dynamic compression plate (DCP), restricted contact dynamic compression plate (LCDCP), and locked compression plate are all options for plating (LCP).<sup>2</sup>

Fixation is usually done with a dynamic compression plate or an interlocking nail. Nailing is known to cause shoulder mobility restriction and delayed union. Up to 20% of patients experience shoulder pain as a result of rotator cuff damage, nail protrusion, or adhesive capsulitis.<sup>3</sup>

According to Shao, secondary radial nerve palsy is a common complication related with humeral plating (2005)<sup>4</sup> Despite the fact that both treatments have advantages and drawbacks, according to Paris H., plate and screw fixation for the middle third of the shaft humerus remains the gold standard for surgical care (2000)<sup>5</sup>.

Anterolateral, posterior, posterolateral, and lateral techniques are used to treat humeral shaft fractures. The most prevalent techniques are anterolateral and posterior. Anterolateral approach incisions that can be prolonged proximally and distally without considerable manipulation of the radial nerve are preferred for exposing middle 1/3rd and proximal shaft fractures. Because of the form of the distal humerus, distal shaft fractures are commonly handled from the back. The radial nerve must be explored and proximal extension is a restriction of this strategy. Iatrogenic or secondary radial

nerve palsy is found to affect 5.1 percent to 17.6 percent of people.<sup>6</sup> Even said, some surgeons favor the posterior technique for all shaft humerus fractures because it allows for easier fracture reduction and fast exposure. Both techniques can safely approach a fracture shaft humerus excluding the proximal and distal 5 cm, depending on the surgeon's discretion. The open reduction and internal fixation (ORIF) with direct fracture exposure often results in near anatomic alignment without impairing elbow and shoulder function.<sup>7</sup> Compression plating is recommended as the best treatment option for humeral shaft fractures that necessitate surgery.<sup>8</sup> The rates of non-union and hardware failure that necessitates revision range from 0% to 7%.<sup>9</sup> By securing the screws to the plate, the plate can be offset from the underlying bone surface, giving a physiologic benefit for bone fracture repair by protecting the periosteal blood flow beneath the plate.<sup>10</sup> When total range of motion is not achieved, the functional range of motion of the elbow and shoulder returns reliably after plate fixation; additional skeletal or neurologic injuries are frequently present.<sup>11</sup>

In terms of treatment, there is no clear consensus on whether or not the nerve should be surgically examined. Patients having early nerve injury have high rate of spontaneous recovery, according to previous literature: a "wait and see" approach found to be commonly supported, and early nerve exploration is only specified in exceptional situations (e.g., open fractures). On the other side, views differ on whether early nerve exploration is required in patients with subsequent nerve palsy following first surgical fracture fixation. While few authors believe for early exploration, others advise against it.<sup>12</sup> Others suggest for a four- or six-month period of observation.<sup>13</sup> According to the research, there is no significant difference between primary radial nerve

palsy (88 percent) and subsequent radial nerve palsy (88 percent) in terms of overall recovery rate (93 percent).<sup>14</sup>

Those who treat the humeral shaft fracture conservatively believe that radial nerve palsy can be avoided. In open reduction internal fixation, radial nerve palsy is a common complication.<sup>15</sup> It is nearly always temporary, and it goes away with time, but it affects both the patients and the surgeon. If there is neuropraxia as proven by conduction testing, the therapy of post-operative radial nerve palsy is primarily conservative. If radial nerve palsy develops after surgery, patients should be reassured and a dynamic splint should be used in the extended position of the wrist and finger, which usually restores nerve function.<sup>16</sup>

Evidence also suggests that immediate weight-bearing on an ORIF-treated upper extremity has little or no negative consequences. Infection and iatrogenic nerve palsy are the most common complications linked with plating treatments (2–5%), with the majority of instances being a temporary condition that requires no further care (0–6%).

## Materials and method

**Study Design:** Descriptive type of study.

**Study Place:** Study was conducted in Department of Orthopaedics of tertiary care centre at the institutional level.

**Study Period:** From the December 2019 to December 2021.

**Study Population:** Patients of humerus shaft fracture visiting O.P.D/ I.P.D and Referrals from other departments of Hospital to Department of Orthopaedics.

**Sample Size:** A total sample size of 30 patients with humerus shaft fractures with radial nerve palsy treated with open reduction and internal fixation with plating.

**Sample size formula:** Sample size  $n = [DEFF * Np(1-p)] / [(d^2 / Z^2_{1-\alpha/2} * (N-1) + p*(1-p)]$

Population size (for finite population correction factor or fpc) ( $N$ ):18

Hypothesized % frequency of outcome factor in the population ( $p$ ):50%+/-5

Confidence limits as % of 100(absolute +/- %) ( $d$ ):5%

Design effect (for cluster surveys- $DEFF$ ):1

## Inclusion Criteria

Middle 1/3 shaft fracture

Recent trauma

Simple closed fracture with radial nerve palsy

## Exclusion criteria

Compound fracture

Non-union or malunion

Associated fractures e.g., Shoulder dislocation or head of humerus fracture.

## Methodology

### Operational definition Appropriate methods of measurement

Approved proformas was used for collecting the data. Written informed consent of all the patients which are included in the study was taken. Prospective, Observation and analytical study was conducted in patients coming to the hospital, fulfilling of inclusion and exclusion criteria diagnosed as humerus shaft fracture with radial nerve injury of the age group 18-75 years.

### Pre-Operative Assessment:

X-ray of the affected arm including one joint above and one joint below; including the ipsilateral shoulder and elbow joints. Minimum two views are necessary: Anteroposterior and Lateral Views. Anteroposterior and lateral radiographs were used to template the exact length of implant. The Fracture pattern was classified according to Orthopedic Trauma Association classification.

**Procedure**

**Surgical approach**

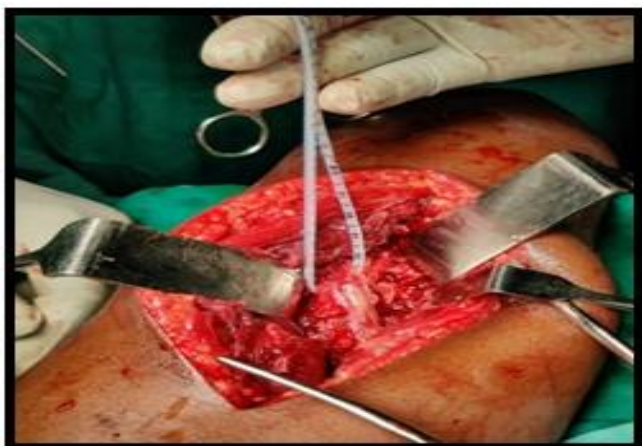

Figure 1: Intraoperative radial nerve isolation

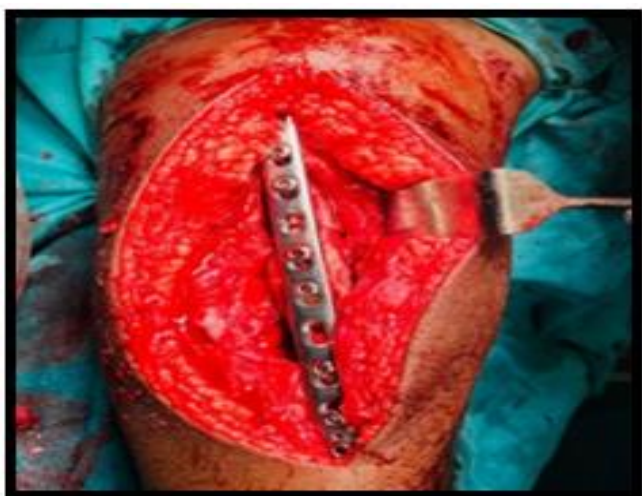

Figure 2: Intraoperative fixation

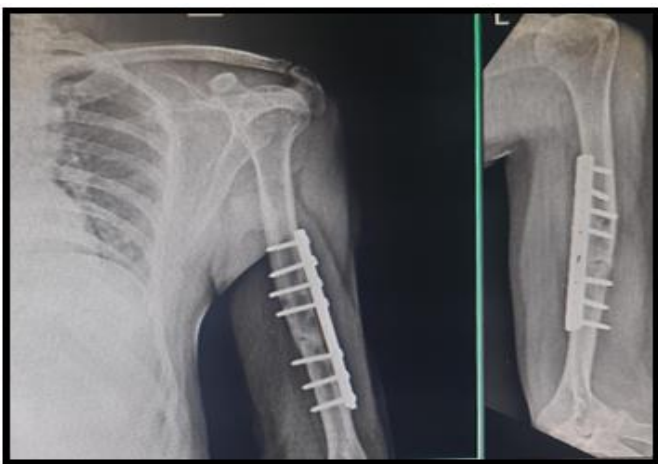


Figure 3: Post operative X ray

**Evaluation**

Postoperative Parameters: General post operative care. Check X-ray of the operated humerus full length in AP and Lateral views was done.

Physiotherapy: Active finger and wrist movements.

Active elbow range of motion depending upon fixation.

Post op dressing.

Assessment of neurovascular deficit: Clinical evaluation.

**Method of data collection relevant to objective**

**Variables studied / measured:**

Sn.	Variable name	Measurement scale	Measurement method
	Primary Variables:		
1.	Pain	Ordinal	Actual measurement
2.	Sensory deficits	Nominal	Actual measurement
3.	Muscle power	Ordinal	Actual measurement
4.	Reflexes	Ordinal	Actual measurement
	Secondary Variables:		
5.	Age	Ratio scale	Interview
6.	Gender	Nominal	Interview

**Statistical analysis**

The data was coded and entered into Microsoft Excel spreadsheet. Analysis was done using SPSS version 20 (IBM SPSS Statistics Inc., Chicago, Illinois, USA) Windows software program. Descriptive statistics included computation of percentages, means and standard deviations. Level of significance was set at  $P \leq 0.05$ .

**Observations and results**

**Descriptive data of the study**

	Minimum	Maximum	Mean	Std. Deviation
Time of surgery	2.00	3.50	2.58	.39
Mean time of radiation	1.30	3.51	2.23	.57
Time of union in weeks	12	20	15.07	2.39
Time since fracture (days)	1	6	3.43	1.77

Mean time of surgery was 2.58 hours, mean time of radiation was 2.23m, mean time of union was 15.07 weeks and mean time since fracture was 3.43 days.

**Complication wise distribution of the study**

	Frequency	Percent (%)
NA	18	60.0
Functional disability	6	20.0
Infection	4	13.3
Nonunion	2	6.7
Total	30	100.0

There were two cases of non-union (6.7%), six case have functional disability (20%) and four case have infection (13.3%).

**Clinical course wise distribution of the study**

Clinical Course	Frequency	Percent (%)
Complete recovery	25	83.3
Partial recovery	5	16.7
Total	30	100.0

Complete recovery was found in 83.3% while partial recovery was found in 16.7%

**Outcome wise distribution of the study**

	Frequency	Percent (%)
Excellent	15	50.0
Fair	4	13.3
Good	3	10.0
Poor	8	26.7
Total	30	100.0

15 (50%) case have excellent result, 3 (10%) case have good result, 4 (13.3%) case have fair result and 8 (26.7%) case have poor result.

**Discussion**

Indications for open reduction and internal fixation of humeral shaft fracture can be based on two criteria: fracture characteristics and presence of associated injuries.<sup>18</sup> The indications for surgery based on fracture characteristics have been described as: open fractures: displaced fractures; fractures located proximally or distally which are more difficult to manage conservatively; displaced or non-union of the fracture and pathologic fracture.<sup>19</sup> Associated injuries include ipsilateral forearm fracture (floating elbow), multiple trauma and presence of neurovascular deficits. The most frequent indication for internal fixation of the shaft of the humerus in several studies was the presence of associated multiple traumas.<sup>20</sup>

In our study, the majority (51.85%) of the patients were in the age group of 50-60 years (46.6%) and mainly of male following road traffic accidents and this was similar to a study from Taiwan.<sup>21</sup> This was again contrary to a report from Scotland, which indicated the highest incidence in patients aged over 50 years.<sup>22</sup> Studies by Ekholm R (2006)<sup>23</sup> et al was found that incidence of these fractures increased from the 5th decade onwards.

Analysis of humeral fractures in general in this study in relation to gender showed that males had a higher incidence than females, as had also been shown from an American study.<sup>24</sup> This might be due to the fact that men are more involved in physically demanding jobs than women. A previous study also showed that men are more involved in road traffic accidents than women.<sup>25</sup>

Of the 30 patients operated on, 26 were right hand dominant while the remaining were left-handed (4).



Mean duration of surgery in our study was 2.58 hrs which was less than for the anterolateral group and comparable to similar study reported by Kirin I et al (2011)<sup>26</sup> which signifies that anteromedial humeral plating is less time consuming compared to other surgical approaches.

In a study carried out by Putti A (2009)<sup>27</sup> he reported a mean time of healing of 16 weeks in patients with DCP plating and 18 weeks in patients treated with nailing. In our study we achieved a mean healing time of 15.07 weeks in patients treated.

There were two cases of non-union, six case have functional disability and four case have infection. 15 (50%) case have excellent result, 3 (10%) case have good result, 4 (13.3%) case have fair result and 8 (26.7%) case have poor result.

Regarding primary or traumatic radial nerve palsy associated with humeral shaft fractures, our study showed a high rate of spontaneous complete recovery of nerve function (83.3%), correlating well with the literature.<sup>28,29,30</sup> Early exploration of the radial nerve in primary traumatic palsy does not seem to be necessary, especially in closed fractures, where a primary serious nerve damage requiring surgical repair is very rare. The literature reported incidence of iatrogenic radial nerve palsy when the plate was placed on anterolateral and posterior surface of humerus was up to 12%<sup>31</sup> and 11.46% (Kirin I et al).

In 18 patients, Venouziou (2016)<sup>32</sup> et al assessed associations between energy of the trauma and nerve recovery. The 8 patients who failed to recover had severe nerve damage after a high-energy trauma. In the patients who recovered, compared to low-energy trauma, high-energy trauma was associated with longer times to initial recovery signs and to full recovery.

The optimal management strategy for radial nerve palsy in the setting of a humeral shaft fracture remains controversial. Shao et al. presented a systematic review of the literature. Spontaneous recovery was documented in 315 of 435 patients with primary radial nerve palsy (RNP) (72%). Of the remaining 120 patients, 104 underwent late exploration at an adjusted mean time of 4.3 months, and 69% had postoperative recovery. Overall, 89% of those initially treated non-operatively achieved functional recovery.<sup>33</sup>

The issue of iatrogenic radial nerve palsy is nerve palsy that develops after surgery. The risk of nerve entrapment at the fracture site or beneath the plate of possible.<sup>34</sup> In a study by Hee et al there was 1.57% secondary radial nerve palsy.<sup>35</sup> In another study by Wang et al the frequency of secondary radial nerve palsy was 4.24%.<sup>36</sup> A study by Botsmann et al showed the frequency of secondary radial nerve injuries to be 2.94% in LCDCP group and 3.63% LCP group.<sup>37</sup> In study by Shunkar et al there was 7.89% secondary radial nerve palsy.<sup>38</sup> The radial nerve was found to be intact intra-operatively as the surgeon was sure that the cause was transient neuropraxia due to traction or tourniquet effect intra-operatively. Follow up of these cases revealed full return of radial nerve function.

Claessen (2015) et al found radial nerve palsy in humeral shaft fractures significantly associated with high-energy trauma, open fractures, as well as surgical approach.<sup>39</sup> Shaw and Bhatti (1983)<sup>40</sup> recommended early exploration in affected patients but found that only 1 in 5 explored nerves required neurorrhaphy. Still advocating early exploration of open fractures with palsy, Foster and colleagues<sup>41</sup> found significantly more morbidity with these injuries; 64% of open humeral fractures with palsy on early exploration had a trapped, partial, or completely lacerated radial nerve. More recently, Ring and

colleagues<sup>42</sup> found that 55% of open humerus fractures had transected radial nerves. Consequently, though there are no prospective randomized controlled trials, most authors and the majority of our survey respondents have agreed that open fractures with radial nerve palsy should be explored primarily. Ekholm (2008)<sup>43</sup> et al. reported the incidence of radial nerve palsy associated with humeral shaft fracture as 8.5% in a population of closed humeral shaft fractures, including 361 traumatic injuries, 34 pathological fractures, and 6 peri-implant fractures. In that study, there were 18 patients with radial palsy who were non-operatively managed; 89% of these patients recovered completely, whereas the remaining 11% were left with minor sequelae from the radial nerve palsy (i.e., dysesthesia).

Other authors have specifically examined fracture location, fracture type, and degree of angulation as indicators for nerve exploration with associated palsy. Vansteenkiste FP (1889)<sup>44</sup> et al advocated exploration for all patients with the Holstein–Lewis fracture and palsy after finding a macroscopic lesion of most nerves in these patients. Böstman and colleagues found that longitudinal fractures of the distal third are significantly more likely than transverse fractures of the middle third to have lacerated, interposed, or entrapped radial nerves. Interestingly, they found no significant difference with regard to recovery between exploration versus observation for these patients.

There are several risks and reasons for a radial palsy during fracture fixation: even light tension to the nerve during exploration might cause neurapraxia. Another potential source for injury is the positioning of the patient before and during surgery. Under general anesthesia, the loss of consciousness along with muscle tone might lead to accidental and excessive movement at the fracture site. Similar traction damage can occur because of excessive

indirect fracture manipulation during nailing. A strong tension to the surrounding radial nerve or an entrapment between bone fragments can be the consequence. Therefore, a temporary fracture immobilization, e.g., with a cast and attention during an aesthetic induction and patient positioning, of both the surgeon and the support personally have to be guaranteed. Great caution should be taken during the approach and the fracture reduction. In the critical region especially from the middle to the distal humeral shaft, where the radial nerve transverses the intermuscular septum, special retraction devices such as Hohmann retractors are dangerous. Their use should be avoided.<sup>45,46</sup>

The posterior approach is usually indicated in the distal third of humeral shaft fractures. For this approach, the patients need to be in a lateral position, which may pose a problem in multiple injuries. It is important to isolate the radial nerve completely before placement of the plate, otherwise there is a risk of nerve entrapment beneath the plate.

### Conclusion

Open reduction and internal fixation of humeral shaft fracture gives good results, if correct indications and principles of fixation are followed. It provides greater patient comfort and is a good alternative to conservative treatment, as unnecessary avoidance of open reduction and internal fixation in fear of intragenic radial nerve palsy, prolongs limb rehabilitation and unemployment of the patients. The outcome of radial nerve palsy was not found to be related to age group, sex, side, mechanism of injury, intra-operative condition of nerve, method of treatment of fracture and time of exploration of radial nerve.

### References

1. Sameer MH, Maheswarappa. Study of functional outcome of humerus shaft fracture in adults treated

- with dynamic compression plating. *J Sci Soc* 2012; 39:114-7
2. Singh AK, Narasaria N, Morrenhof JW, Janzing HM. Surgical versus non-surgical intervention for treating humeral shaft fracture in adults. *Cochrane Database Syst Rev* 2012.
  3. Bhandari M, Devereaux PJ, McKee MD, Schemitsch EH. Compression plating versus intramedullary nailing of humeral shaft fractures: a meta-analysis. *ActaOrthop* 2006;77:279-84
  4. Shao YC, Harwood P, Grotz MR, Limb D, Giannoudis PV. Radial nerve palsy associated with fractures of the shaft of the humerus: a systematic review. *J Bone Joint Surg Br* 2005;87(12):1647-52
  5. Paris H, Tropiano P, Clouet D'orval B, Chaudet H, Poitout DG. Fractures of the shaft of the humerus: systematic plate fixation. Anatomic and functional results in 156 cases and a review of the literature. *Rev ChirOrthopReparatriceAppar Mot* 2000;86:346-59.
  6. Lim KE, Yap CK, Ong SC. Aminuddin Plate osteosynthesis of the humerus shaft fracture and its association with radial nerve injury: a retrospective study in Melaka General Hospital. *Med J Malaysia* 2001;56(Suppl C):8-12
  7. Mahmoud MH, Amr ED, Mustafa MK. Minimally invasive plate osteosynthesis versus open reduction and plate fixation of humeral shaft fractures. *Menoufia Med J* 2015;28:154-61.
  8. Naill DM, O'Mahony J, McElwain JP. Plating of humeral shaft fractures has the pendulum swung back? *Injury* 2004;35:580-6.
  9. Paris H, Tropiano P, Clouet D'orval B, Chaudet H, Poitout DG. Fractures of the shaft of the humerus: Systematic plate fixation. Anatomic and functional results in 156 cases and a review of the literature. *Rev ChirOrthopReparatriceAppar Mot* 2000;86:346-59
  10. Klaue K, Fengels I, Perren SM. Long-term effects of plate osteosynthesis: Comparison of four different plates. *Injury* 2000;31 Suppl 2:S-B51-62.
  11. Gregory PR, Sanders RW. Compression plating versus intramedullary fixation of humeral shaft fractures. *J Am AcadOrthopSurg* 1997;5:215-23.
  12. Kwasny O, Maier R, Kutscha-Lissberg F, Scharf W. Treatment procedure in humeral shaft fractures with primary or secondary radial nerve damage. *Unfallchirurgie* 1992;18(3):168-73
  13. Wang X, Zhang P, Zhou Y, Zhu C. Secondary radial nerve palsy after internal fixation of humeral shaft fractures. *Eur OrthopSurgTraumatolOrthopTraumatol* 2014;24(3):331-3.
  14. Korompilias AV, Lykissas MG, Kostas-Agnantis IP, Vekris MD, Soucacos PN, Beris AE. Approach to radial nerve palsy caused by humerus shaft fracture: is primary exploration necessary? *Injury* 2013.
  15. Claessen Fm, Peters RM, Verbeek DO et al. Factors associated with radial nerve palsy after operative treatment of diaphyseal humeral shaft fracture. *J Shoulder Elbow Surg* 2015;24: e307-11.
  16. Niver GE, Ilyas AM. Management of radial nerve palsy following fracture of the humerus. *Orthop Clin NOrthAmeriaca* 2013; 44:419-24.
  17. Chandra PP, Amrit G, Rajendra KS, Deepak K, Arpit S, Karuna SK. A comparative study of the results of locking compression plating and stack nailing in diaphyseal fracture of humerus. *J Orthop Trauma Rehab* 2013; 6:74-7.
  18. Mani KK, Sagar DG, Rijal L et al. Study on outcome of fracture shaft of the humerus treated non-



- operatively with a functional brace. *Europe J Ortho Surg Trauma* 2013; 23:323-328.
19. Srinivas K, Rajaiah D, Ramana Y et al. Humerus, diaphyseal fracture dynamic compression plate. A study of surgical management of diaphyseal fracture of humerus by dynamic compressive plate osteosynthesis 2015; 4:1290-6
  20. Tytherleigh-Strong G, Walls N, McQueen MM. The epidemiology of humeral shaft fractures. *J Bone Joint Surg.* 1998; 80-B:249-53
  21. Tsai CH, Fong YC, Chen YH, Hsu CJ, Chang CH, Hsu HC. The epidemiology of traumatic humeral shaft fractures in Taiwan. *Internet Orthop (SICOT).* 2009; 33(2): 463-7.
  22. Laing PG. The arterial supply of the adult humerus. *J Bone Joint Surg.* 1956; 38 (5): 1105-16.
  23. Ekholm R, Adami J, Tidermark J et al. Fractures of the shaft of the humerus. An epidemiological study of 401 fractures. *J Bone Joint Surg* 2006; 88-B : 1469-1473
  24. McCormack RG, Brien D, Buckley RE, McKee MD, Powell J, Schemitsch EH. Fixation of fractures of the shaft of the humerus by dynamic compression plate or intramedullary nail: A prospective randomized trial. *J Bone Joint Surg.* 2000; 82(3): 336-9.
  25. Raghavendra S, Bhalodiya HP. Internal fixation of fractures of the shaft of the humerus by dynamic compression plate or intramedullary nail: A prospective study. *Indian J Orthop.* 2007; 41(3): 214-8.
  26. Kirin I, Jurisic D, Grebic D, Nadalin S. The advantages of humeral anteromedial plate osteosynthesis in the middle third shaft fractures. *Middleast J Med.* 2011; 123(3-4): 83-7.
  27. Putti AB, Uppin RB, Putti BB. Locked intramedullary nailing versus dynamic compression plating for humeral shaft fractures *Journal of Orthopaedic Surgery* 2009;17(2): 139-41.
  28. Korompilias AV, Lykissas MG, Kostas-Agnantis IP, Vekris MD, Soucacos PN, Beris AE. Approach to radial nerve palsy caused by humerus shaft fracture: is primary exploration necessary? *Injury.* 2013
  29. Grassmann JP, Jungbluth P, Bullermann L, Hakimi M, Gehrmann SV, Thelen S, Betsch M, Windolf J, Wild M. Radial nerve palsy associated with humeral shaft fractures—early exploration or expectant procedure? An analysis concerning current strategies of treatment. *Zeitschrift fur OrthopadieUnfallchirurgie* 2010;148(6):691–6.
  30. Grass G, Kabir K, Ohse J, Rangger C, Besch L, Mathiak G. Primary exploration of radial nerve is not required for radial nerve palsy while treating humerus shaft fractures with unreamed humerus nails (UHN). *Open Orthop J.* 2011; 5:319–23
  31. Livani B, Belangero W, Medina G, Pimenta C, Zogiab R, Mongon M, et al. Anterior plating as a surgical alternative in the treatment of humeral shaft non-union. *Internet Orthop(SICOT).* 2010; 34(7): 1025-31.
  32. Venouziou AI, Dailiana ZH, Varitimidis SE, Hantes ME, Gougoulas NE, MalizosKN. Radial nerve palsy associated with humeral shaft fracture. Is the energy of trauma a prognostic factor? *Injury* 2011;42:1289–93.
  33. Shao YC, Harwood P, Grotz MR, Limb D, and Giannoudis PV. Radial nerve palsy associated with fractures of the shaft of the humerus: a systematic review. *J Bone Joint Surg Br* 2005;87:1647–52
  34. Griend RV, Tomasin J, Ward EF. Open reduction and internal fixation of humeral shaft fracture. *J Bone Joint Surg* 1986;68A:430-3.

35. Hee HT, Low BY, See HF. Surgical results of open reduction and plating of humeral shaft fracture. *Ann Acad Med Singapore* 1998;27:772-5.
36. Wang JP, Shen WJ, Chen Wm et al. Iatrogenic radial nerve palsy after operative management of humeral shaft fracture. *J Trauma Acute Care Surg* 2009;66:800-3.
37. Bostman O, Bakalim G, Vainionpaa S et al. Radial palsy in shaft fracture of the humerus. *Acta Orthop* 1986;57:316-9.
38. Shankar PR, Iytha MS, Pusarla A et al. Effectiveness of locking versus dynamic compression plates for diaphyseal humerus fractures. *J Evidence Based Med Healthcare* 2015;2:693-8.
39. Claessen FM, Peters RM, Verbeek DO, Helfet DL, Ring D. Factors associated with radial nerve palsy after operative treatment of diaphyseal humeral shaft fractures. *J Shoulder ElbSurg Am Shoulder ElbSurg* 2015;24(11):e307–11
40. Shaw JJ, Bhatti NA. Radial nerve paralysis associated with fractures of the humerus. A review of 62 cases. *Clin Orthop*. 1983;(172):171-176.
41. Foster RJ, Swiontkowski MF, Bach AW, Sack JT. Radial nerve palsy caused by open humeral shaft fractures. *J Hand Surg Am*. 1993;18(1):121-124.
42. Ring D, Chin K, Jupiter JB. Radial nerve palsy associated with high energy humeral shaft fractures. *J Hand Surg Am*. 2004;29(1):144-147.
43. Ekholm R, Ponzer S, Törnkvist H, Adami J, Tidermark J. Primary radial nerve palsy in patients with acute humeral shaft fractures. *J Orthop Trauma* 2008;22(6):408–414
44. Vansteenkiste FP, Rommens PM, Broos PL. Is a radial nerve paralysis in a humeral shaft fracture an indication for surgery? *Acta ChirBelg* 1989;89(4):215-220
45. Wang X, Zhang P, Zhou Y, Zhu C. Secondary radial nerve palsy after internal fixation of humeral shaft fractures. *EurOrthop SurgTraumatol Orthop Traumatol*. 2014;24(3):331–3
46. Hak DJ. Radial nerve palsy associated with humeral shaft fractures. *Orthopedics*. 2009;32(2):1