

Study of histopathological placental changes in hypertensive diseases of pregnancy

¹Dr. Vaishnavi Anil Ujawane, Junior Resident, Dr Punjab Rao Deshmukh Memorial Medical College.

²Dr. Anil T. Deshmukh, Professor and Dean, Dr Punjab Rao Deshmukh Memorial Medical College.

³Dr. Nafees Noman, Assistant professor, Dr Punjab Rao Deshmukh Memorial Medical College.

⁴Dr. Chetna Agrawal, Assistant professor, Dr Punjab Rao Deshmukh Memorial Medical College.

Corresponding Author: Dr. Vaishnavi Anil Ujawane, Junior Resident, Dr Punjab Rao Deshmukh Memorial Medical College.

Citation this Article: Dr. Vaishnavi Anil Ujawane, Dr. Anil T. Deshmukh, Dr. Nafees Noman, Dr. Chetna Agrawal, “Study of histopathological placental changes in hypertensive diseases of pregnancy”, IJMSIR- August - 2023, Vol – 8, Issue - 4, P. No. 52 – 58.

Type of Publication: Original Research Article

Conflicts of Interest: Nil

Abstract

Background: The placenta, foetus, and mother form a composite functional equilibrium during prenatal period. Hypertensive disorder of pregnancy, a well-known medical complication of pregnancy is potentially morbid for the fetomaternal health. It is one of the common complications in pregnancy and contributes significantly to maternal and fetal morbidity and mortality. Hypertension related changes in pregnancy are seen both microscopically and macroscopically. They remain the major causes of maternal and perinatal mortality.

Aim and Objective:

To analyse the morphological changes in the placenta of pregnant patients with hypertensive disease.

To draw necessary conclusions from the study and make a correlation of the results with those available from similar previous studies.

Materials and Methods: This was a cross-sectional study. We included 150 pregnant women with hypertensive disorders of pregnancy. Specimens of placenta from each case were collected after delivery and

processed by routine histopathology technique. We looked for morphological and histological changes in placenta. We also collected the data on placental weight, fetal weight, any. The data was processed on Microsoft Excel was used for statistical analysis by SPSS version 22.

Results: We found statistically significant reduction in placental weight, diameter and thickness among cases and there is also a strong correlation with the histopathological changes of placenta in hypertensive mothers to fetal weight. Gross and microscopic changes like areas of infarction and calcification were more evident in hypertensive mothers. The percentage of villi with syncytial knots >30% was seen in 69.33% of cases which was a significant finding on microscopy. Along with that areas of stromal fibrosis and fibrinoid necrosis were seen.

Conclusion: Hypertensive disorders of Pregnancy causes significant histomorphological changes in placenta leading to adverse fetal outcome.

Keywords: Pregnancy, Hypertension, Disorders.

Introduction

The Organ placenta is of critical importance for intrauterine existence of foetus. It is a fetomaternal organ involved in nutrition, waste elimination and gas exchange between the developing foetus and mother.

Hypertensive disorder of pregnancy, a well-known medical complication of pregnancy is potentially morbid for the fetomaternal health. It is one of the common complications in pregnancy and contributes significantly to maternal and fetal morbidity and mortality.

Hypertension related changes in pregnancy are seen both microscopically and macroscopically. The uteroplacental blood flow is decreased in hypertensive patients due to maternal vasospasm which leads to constriction of fetal stem arteries and has been associated with changes seen in placenta of preeclamptic women.

Maternal vasospasm leads to fetal distress which can cause intrauterine growth restriction and/or intrauterine death.

Detailed examination of placenta post-delivery, provides much insight into the prenatal health of the baby and the mother.

The vascular and villous changes seen in the placenta in hypertensive disease of pregnancy are thought to be associated with placental insufficiency.

Aims & Objective

To analyse the morphological changes in the placenta of pregnant patients with hypertensive disease.

To draw necessary conclusions from the study and make a correlation of the results with those available from similar previous studies.

Material & Methods

Study design: Cross sectional study.

Study population: All patients of hypertensive disease of pregnancy admitted in Tertiary Care Hospital.

Study setting: Histopathological laboratory in Tertiary Care Hospital.

Study duration: 18 months.

Sampling methods: Purposive sampling.

Sample size: We included 150 pregnant women with hypertensive disorders of pregnancy. The data was processed on Microsoft Excel and SPSS version 22 was used for statistical analysis.

Inclusion Criteria

- Must be an adult (>18yrs)
- All females with hypertensive disease of pregnancy.

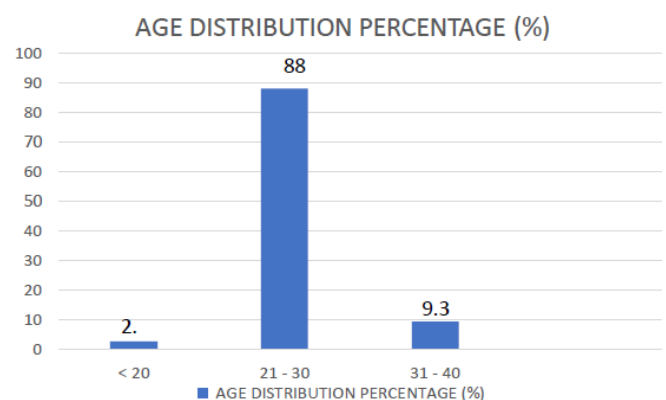
Exclusion criteria

- Molar pregnancies, multiple pregnancies.
- HIV positive cases with known end stage processes.
- Patients with diabetes mellitus, anaemia, sepsis, hepatitis, coagulopathies, placenta previa.

Observations & Results

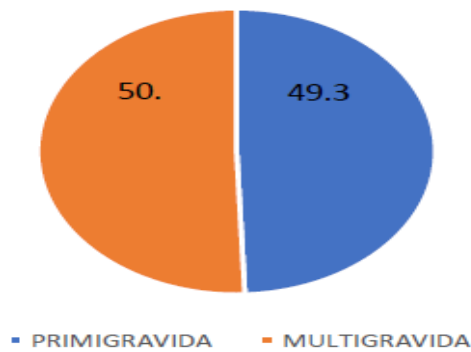
In the present study a total of 150 placentae were studied, all of them are collected from different categories of hypertensive disorders of pregnancy.

The distribution of cases of hypertensive patients revealed maximum number of cases in the preeclampsia group.



Maximum number of cases were in age group 21-30 years. Mean age calculated is 25.44 ± 3.57

DISTRIBUTION OF CASES ACCORDING TO GRAVIDA STATUS

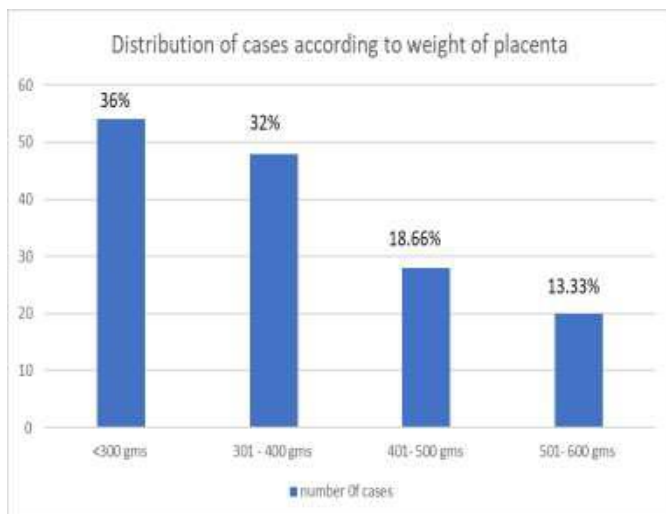


Almost equal number of cases of primigravida (49.33%) and multigravida patients (50.66%) were seen in this study.

In this study maximum reduction in fetal weight was noted in preeclamptic (60%) and eclamptic group (88%) giving a significant finding.

Gross parameters in hypertensive patients

Weight of the placenta in HTN groups

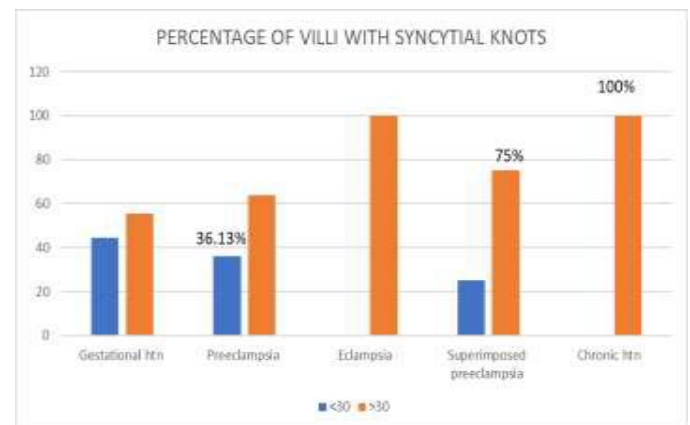


The study observed maximum cases with reduction in placental weight. The weight of placenta less than 300gms was seen in total 54 (36%) cases. The average weight calculated of all Hypertensive cases is around 356.66.

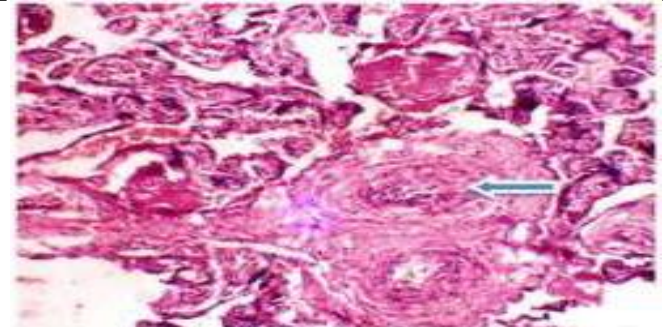
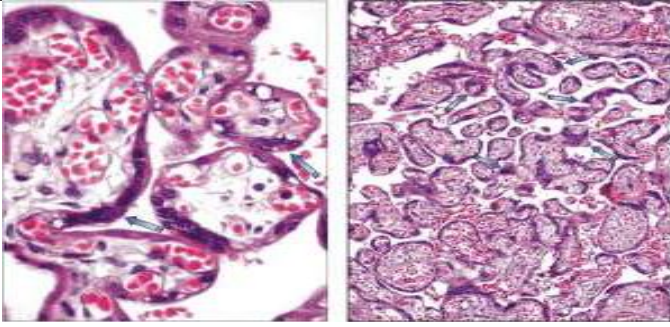
	NUMBER OF CASES	Percentage (%) out of 150.
1) Umbilical cord insertion		
Central	76	50.66 %
Eccentric	68	45.33%
Marginal	06	4%
Velamentous	-	-
Single umbilical artery	03	-
Mean umbilical cord length	30.28 ± 8.49	
Knots in umbilical cord	05	
2) PLACENTAL SIZE		
MEAN DIAMETER	16.19 ± 2.55	
MEAN THICKNESS	1.85 ± 0.54	
3) Placental shape		
Round	73	48.66%
Oval	65	43.33%
Irregular	12	8%
4) Number of cotyledons (mean + SD)	17.82 ± 3.19	

Microscopic findings in hypertensive patients

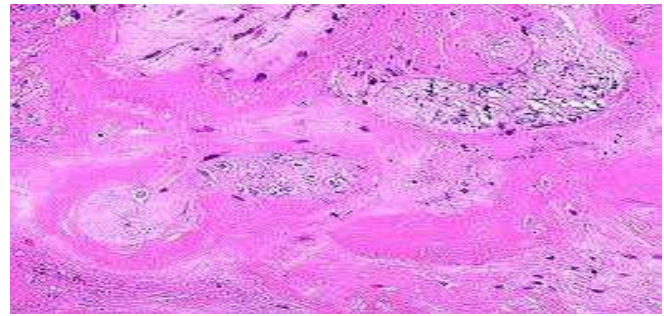
Percentage of villi with syncytial knots



The percentage of villi with syncytial knots >30% was seen in 100% of cases eclampsia and chronic HTN Cases which was a significant finding on microscopy.



Areas of stromal fibrosis seen in terminal villi



Areas of fibrinoid necrosis

1. Tenn parker changes /syncytial knots

In preeclampsia, there is increased budding of placental syncytium, attributed to low oxygen levels inducing angiogenesis, resulting in clusters of short, highly branched and notched terminal villi, showing syncytial knot or Tenney-Parker change. It features clustering of syncytial cytoplasm and agglomeration of nuclei, at the villous surface. Such knots are normally found in preterm and diagnostic of per fusional compromise.

2. Percentage of villi with vasculosyncytial membranes

The present study showed significant vasculo-syncytial membrane deficiency in preeclamptic cases (77.3%) and eclamptic group (83.3%).

3. Areas of stromal fibrosis

This study shows increased number of areas of stromal fibrosis.

4. Areas of fibrinoid necrosis

Increased areas of fibrinoid necrosis are seen in this study

5. Areas of calcification and infarction

Calcification is regarded as evidence of placental senescence or degeneration.⁷¹It is not associated with adverse fetal outcome. In present study there are increased areas of calcification and infarction in eclamptic and preeclamptic group.

Discussion

Hypertensive disorders of pregnancy is the one of leading causes of maternal and perinatal mortality and morbidity. The etiopathogenesis of hypertensive disorders of pregnancy still remains a subject of controversy.

The classical view in this regard focuses on the placenta and the utero placental circulation. Although the study of the placenta is, retrospective in nature, yet it provides a reflection of hazards the foetus has been subjected to during its growth and development.

It is difficult to define the normal placental findings and differentiate it from the abnormal, because of the structural complexity and rapid evolution of the placenta.

Weight of the placenta and weight of foetus: Normally a placenta weighs from 400 to 800gms. This study observed the reduction of placental weight in the hypertensive disorders. Bandana Das et al (1996) Sharma (1981), Dutta (1989) also reported the same findings.

Diameter and thickness -Diameter and thickness were both reduced in the hypertensive group. The mean diameter and thickness in this study is 16.19 and 1.85

respectively. But this reduction was not statistically significant. According to Bandana Das et al (1996) Diameter and thickness both were reduced in hypertensive group and there was more reduction in thickness than in diameter. The study by Mallik et al. reported that the mean diameter of placenta was 17.54 cm.

Shape of placenta-in present study maximum placentae are round followed by oval followed by irregular. The study conducted by Rehman et al⁶⁹also found that most placentae were round in both groups, but Goswami et al⁷³observed more irregular placentae in preeclamptic group. Shah RK et al⁸⁰, like the present study, observed no clinical significance in the shape of placentae.

Cord insertion-in present study the cord insertion was central in 50.66 %, eccentric in 45.33% and marginal in 4% cases. Whereas the earlier studies by Nobis and Das, the pattern of cord insertion was central in 44.19%, eccentric in 42.17%, and battledore in 1.26%.

In the study group, the histology revealed various structural changes such as significant number of syncytial knots, areas of fibrinoid necrosis, areas of stromal fibrosis, areas of calcification and villi covered by vasculosyncytial membranes.

Villi with syncytial knots -The percentage of villi with syncytial knots >30% was seen in 69.33% of cases which was a significant finding on microscopy.

Vasculo-syncytial membranes in less than 5% of the placental villi is considered significant. The present study showed significant vasculo-syncytial membrane deficiency in preeclamptic cases and eclamptic group. These findings were comparable with studies done by Narasimha A et al⁵³and Navbir⁹⁰, who also reported a significant association between this morphologic parameter and the disease.

Fibrinoid necrosis in up to 3% of placental villi is considered normal. It is considered a hallmark of an immunological reaction within the trophoblastic tissue. The findings of present study are significant (p-value < 0.001) and is in accordance with studies done by Narasimha A et al⁵³and Navbir⁹⁰who showed similar lesion in the placental villi.

Areas of calcification -In the present study, the calcification was present more in eclamptic group. Increased calcification was observed in the studies done by Manjunatha HK et al⁷²and Goswami PR et al⁷³. No statistical significance was observed between the two groups by Das^{SR}.

Conclusion

Hypertensive disorders of Pregnancy cause significant histomorphological changes in placenta leading to adverse foetal outcome.

From the present study it can be concluded that, the hypertensive disorders of pregnancy, adversely influence the morphology of the placenta.

The microscopic changes observed in placentae of patients with hypertensive disorders of pregnancy like –

- Increased in syncytial knots.
- Deficiency of vasculosyncytial membrane
- Increased areas of stromal fibrosis and fibrinoid necrosis
- Calcification and infarction areas

All these are one of the important factors that affect the perinatal outcome.

Take Home Message

we tried to present the current understanding of hypertensive disorders focusing on fetal growth retardation, mild or severe complications and relation of hypertensive diseases with cardiovascular risk factors.

Hence, the earlier the disorder is diagnosed and confirmed, the better the fetal and maternal outcomes are.

Thus, this is the reason why it is necessary to find out the risk factors in high-risk patients through appropriate screening methods.

This will allow early detection and early management, thus ensuring better outcomes for both mother and child. To support this, the study of the histopathology involved in the placenta due to hypertensive disorders can be beneficial, so placentae should not be discarded and detailed macroscopic and microscopic examination is necessary.

References

1. Benirschke K. Abortions and moles. In: Naeye RL, Kissane JM, Kaufman N (Eds) Perinatal diseases. International Academy of Pathology Monograph, Baltimore Williams & Wilkins; 1981: 23-48.
2. Bewly S, Cooper D, Campbell S. Doppler investigation of utero-placental blood flow resistance in the second trimester. A screening study for pre-eclampsia and intra-uterine growth retardation. Br J ObstGynaecol. 1991;98:71
3. Stock MK, Anderson DF, Phernetton TM, McLaughlin MK, Rankin JH. Vascular response of the maternal placental vasculature. J Dev Physiol. 1980;98:871-9.
4. Thomson AM, Billewicz, Hytten FE. Placenta in relation to birth weight. J ObstetGynecolBr CW. 1969;76: 865-72.
5. Dicke JM. Placenta: chronicle of intrauterine growth restriction. F1000 MedRep 2010; 2: 69.
6. Benirschke K, Kaufman P, Baergen RN. The Pathology of Human Placenta. 5th ed. New York, NY: Springer-Verlag; 2006.
7. Benirschke K. The placenta in the context of history and modern medical practice. Arch Pathol Lab Med 1991; 115: 663-667
8. Getzowa S, Sadowsky A. On the structure of the human placenta with full-term and immature foetus, living or dead. J ObstetGynaecolBr Emp 1950; 57: 388-396.
9. Becker V, Bleyl U. Placental villi in pregnancy toxemias and fetal erythroblastosis in the fluorescent microscopy picture. Virchows Arch Pathol Anat Physiol Klin Med 1961; 334: 516-527.
10. Bandana Das, D. Dutta, S. Chakraborty, P. Nath: Placental morphology in hypertensive disorders of pregnancy and its correlation with fetal outcome. J Obstet and Gynecol India, 1996; 46(1): 40-46
11. Dutta D.K., and B. Dutta: Study of human placentae associated with preeclampsia and essential hypertension in relation to foetal outcome. J Obstet and Gynecol India, 1989; 39(6): 757-763
12. Bhatia A, Sharma SD, Jalnawalla S. Fetal 1981: A comparative study of placental pathology and fetal outcome. Indian J Pathol. Microbiol 24: 277-283.
13. Goswami PR, Shah SN. Placenta in normal and pregnancy induced hypertension in relation to its clinical significance: A Gross Study. 2016; 4(7): 58-61.
14. Rehman MZ, Fareedulla HM, Taj N, Malik ZI, Ullah E. Unfavourable effects of pre-eclampsia on the morphology of the Placenta. Pak J Med Health Sci. 2013; 1: 207-211
15. Shah RK, Jagiwal KS, Vyas PK. Placental morphology and fetal growth in normal and abnormal pregnancies. J ObstetGynecol India 1985; 35: 1089-94
16. Sodhi S, Mohan H, Jaiswal TS, Mohan PS, Rathee S. Placental pathology in preeclampsia eclampsia syndrome. Indian J Pathol Microbiol 1990; 33(1): 11-16

17. NavbirP, Alka N, AntimaG. Histological changes in placentae in pregnancies complicated by preeclampsia and eclampsia and correlation with fetal outcome. *Int J Pharm Bio Sci* 2012; 3(2): 551-560.
18. PrakeshJ, Pandey LK, Singh AK, Kar B. Hypertension in pregnancy: hospital-based study. *J Assoc Physicians India*. April 2006; 54: 273-278.
19. S. Rajyalakshmi, Placental pathology in different degrees of pregnancy induced hypertension (PIH) study. *Tropical Journal of Pathology & Microbiology*. December, 2019/ Vol 5/ Issue 12.