

**Nasal Rhinosporidiosis – A rare case report with review of literature.**

<sup>1</sup>Nanda Patil, Professor, Department of Pathology, Krishna Vishwa Vidyapeeth, Karad-415110, Maharashtra.

<sup>2</sup>Shefali Mishra, Senior Resident, Department of Pathology, Krishna Vishwa Vidyapeeth, Karad-415110, Maharashtra.

<sup>3</sup>Vaibhav Chavan, Junior Resident, Department of Pathology, Krishna Vishwa Vidyapeeth, Karad-415110, Maharashtra.

**Corresponding Author:** Vaibhav Chavan, Junior Resident, Department of Pathology, Krishna Vishwa Vidyapeeth, Karad-415110, Maharashtra.

**Citation this Article:** Nanda Patil, Shefali Mishra, Vaibhav Chavan, “Nasal Rhinosporidiosis – A rare case report with review of literature”, IJMSIR- July - 2023, Vol – 8, Issue - 4, P. No. 44 – 47.

**Type of Publication:** Case Report

**Conflicts of Interest:** Nil

**Abstract:** Rhinosporidiosis is a chronic granulomatous infectious disease caused by Rhino sporidium seeberi. The disease is endemic in tropical and subtropical areas and spreads to aquatic exposures. It affects mucosal membrane of the nose, nasopharynx and conjunctiva. We present a case of Nasal Rhinosporidiosis in a 24-year-old male patient presented with nasal of obstruction and epistaxis.

**Keywords:** Rhinosporidiosis, nasal obstruction, chronic granulomatous disease.

**Introduction**

Rhinosporidiosis is a localised chronic granulomatous disease which is caused by protistan parasite Rhinosporidium seeberi which is endemic in many parts of India. (1) The organism was named after R. Seeber who first described this lesion in Argentina. Guillermo Seeber published the first case of Rhinosporidiosis in 1900.

(2,3) The incidence of disease is 1.4% in endemic areas of India. We report a case of Nasal Rhinosporidiosis in a 24-year male patient presented with nasal obstruction and epistaxis.

**Case report**

A 24-year-old male patient presented with difficulty in breathing for eight months. Patient gave history of epistaxis from right nostril along with gradually progressive nasal blockage since six months. The patient was resident of South India and give history of bathing in pond.

Local examination revealed mulberry shaped mass arising from right nasal cavity. (Figure 1).

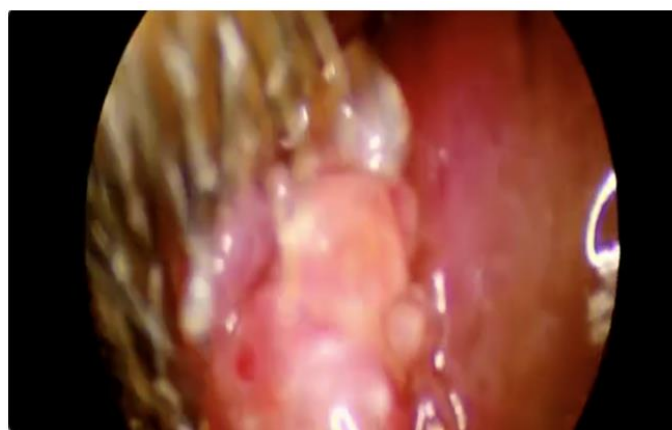

Figure 1: Mulberry shaped mass arising from right nasal cavity.

HRCT revealed a well-defined hypo to iso dense lesion noted in right anterior nasal cavity – Suggesting benign nature. (Figure 2)

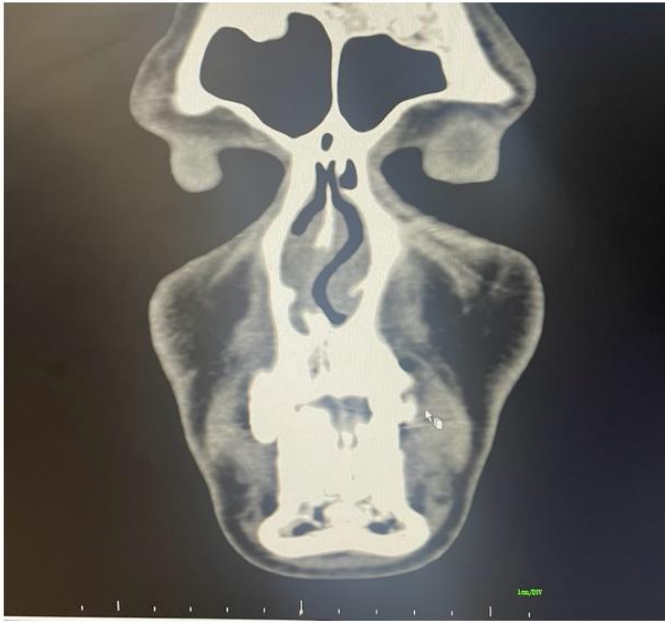

Figure 2: A well-defined hypo to iso dense lesion noted in right anterior nasal cavity.

Complete endoscopic excision of the mass was done after cauterisation of the base under general anesthesia and tissue was sent for histopathological examination. Patient was advised to take tablet Dapson.

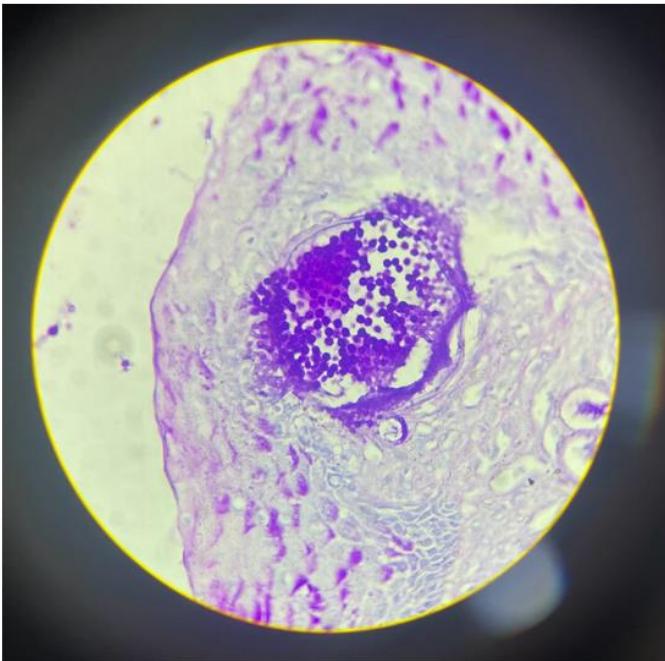


Figure 3: PAS stain highlights endospores and sporangia. (400x)

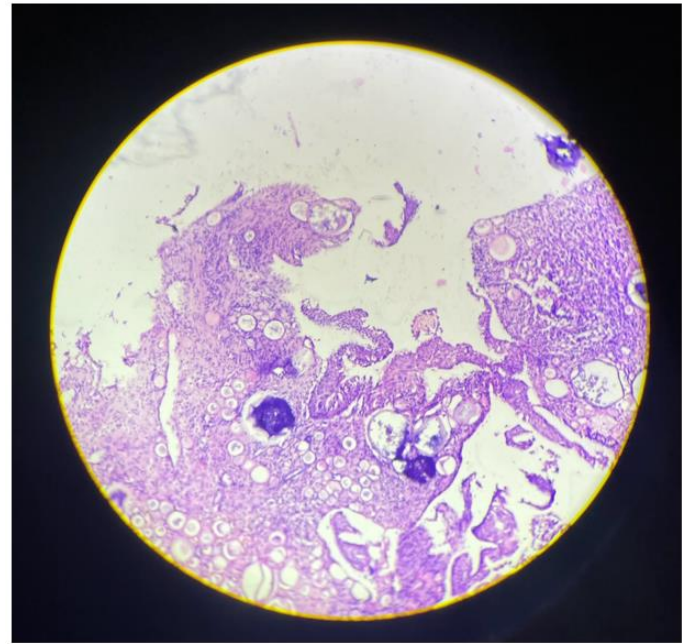


Figure 4: Hyperplastic respiratory epithelium with numerous globular cyst like structures containing thick wall sporangia with numerous endospores. (H&E stain 100x)

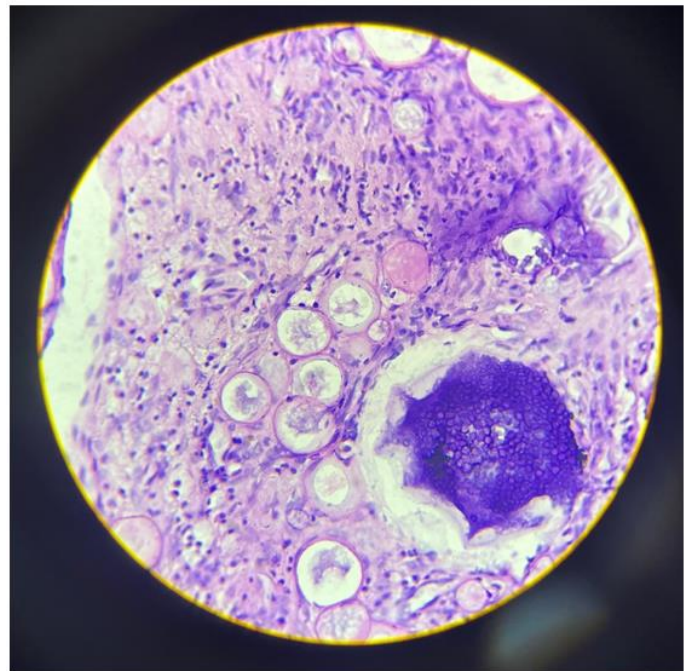


Figure 5: Subepithelial tissue showed inflammatory cells like numerous lymphocytes, plasma cells, few neutrophils, histiocytes and giant cells. (400x H&E)

## Discussion

Rhinosporidiosis is a rare infectious disease caused by *Rhinosporidium seeberi* an aquatic eukaryote that infects human and animals. Aquatic animals like fish and reptiles are common host of this organism while humans are rare host. (4 5) Many microbiologists and pathologists consider this organism as a fungus but its taxonomy is still up for debate. (6)

The disease is most common in tropical and subtropical areas including South India and Sri Lanka. (7) Our patient is also from part of South India which serves as excellent example. Modes of transmission are stagnant water, pond, contaminated sand or soil which have been linked to occupation as a swimmer and agriculturist. (8) Our patient was also involved in frequent activities with water exposures. *Rhinosporidium seeberi* enters the mucosa through the traumatized epithelium and requires wet surface for its proliferation. It affects mucosal sites in the body mainly nasal cavity, nasopharynx followed by ocular cutaneous, ear and genital epithelium. (6) In 53 % - 58 % cases the lesion is found in nasal cavity and patient presents with strawberry like polypoidal tumor like mass obstructing the nasal cavity as seen in our case. Patient may have symptoms such as foreign body sensation, rhinorrhea, nasal blockage and epistaxis. (9) Similar observation was noted in our case. Although CT PNS and MRI determine the extent of disease, definitive diagnosis is done by histopathological examination.

In histological section the organism is seen as oval sporangia on the stages of development which contains hundreds of endospores. (10) Fungal stains such as mucicarmine, Periodic acid-Schiff, Gomori methemine silver can also be used for diagnosis. Antimicrobial drugs used are Amphotericin B, Dapsone, ketoconazole, trimethoprim – sulphadiazine and sodium stibogluconate. (11) Laser assisted endoscopic excision in combination

with Dapsone is effective treatment for Rhinosporidiosis.

Despite this treatment modality there is high rate of recurrence ranging from 10 to 70% due to spillage of sporangia seeding after removal. (12,13) six month follow up in our case is uneventful.

## Conclusion

Rhinosporidiosis is a rare and chronic granulomatous infection commonly affecting nasal cavity. It mimics neoplastic pathology and other inflammatory conditions. Histopathological examination helps in arriving a final diagnosis.

## Reference

1. Mathew S, Arora RD, Prabha N, Kamble P, Satpute SS, Nagarkar NM. Retroanalytical Study of Epidemiological Factors of Rhinosporidiosis Int Arch Otorhinolaryngol. 2020;25:e504–e508 PMID: 34737820; PMCID: PMC8558948
2. Fredricks DN, Jolley JA, Lepp PW, Kosek JC, Relman DA. *Rhinosporidium seeberi*: A human pathogen from a novel group of aquatic protistan parasites Emerg Infect Dis. 2000;6:273–82
3. Kumar S, Mathew J, Cherian V, Rozario R, Kurien M. Laryngeal rhinosporidiosis: Report of a rare case Ear Nose Throat J. 2004;83:568–570
4. Agha R.A., Franchi T., Sohrabi C., Mathew G., for the SCARE Group The SCARE 2020 guideline: updating consensus Surgical Case Report (SCARE) guidelines. Int. J. Surg. 2020;84:226–230.
5. Morelli L. Human nasal rhinosporidiosis: an Italian case report. Diagn. Pathol. 2006;1(1):25.
6. Raquel Vilela et al. The taxonomy and phylogenetics of the human and animal pathogen *Rhinosporidium seeberi*: a critical review. Rev Iberoam Micol. 2012; 29(4):185-19
7. Das S. Nasal rhinosporidiosis in humans: new interpretations and a review of the literature of this

- enigmatic disease. *Med. Mycol.* 2011 Apr  
1;**49**(3):311–315.
8. Bhargava S. Rhinosporidiosis: intraoperative cytological diagnosis in an unsuspected lesion. *Case Rep. Pathol.* 2012 Oct;**11**(2012):101832.
9. Morelli L, Polce Mario, Pisciolli Francesco, Nonno Del Franca, Covella Renato, Brenna Alessia et al. Human nasal rhinosporidiosis: an Italian case report, *Diagn. Pathol.* 2006;1(1):1:25.
10. Prabhu SM, Irodi A, Khiangte HL, Rupa V, Naina P. Imaging features of rhinosporidiosis on contrast CT *Indian J Radiol Imaging.* 2013;23:212–8
11. Arseculeratne SN. The chemotherapy of rhinosporidiosis: A review *J Infect Dis Antimicrob Agents.* 2009;26:21–7
12. Mishra LK, Gupta S, Pradhan SK, Baisakh MR. Lacrimal sac rhinosporidiosis *Plast Aesthet Res.* 2015;2:353
13. <https://www.ncbi.nlm.nih.gov/pmc/articles/PMC8857457/>