

Surgically Placed Subcostal Transversus Abdominis Plane Catheter Infusion for Post Operative Analgesia in Upper Abdomen Surgeries - A Case Series

¹Sandhya M K, Department of Anesthesiology, Kanachur institute of medical Sciences, Mangalore, Karnataka, India.

²Kiran Kumar, Department of Surgery, Kanachur institute of medical Sciences, Mangalore, Karnataka, India.

³Sambhram Shenoy, Department of Anesthesiology, Kanachur institute of medical Sciences, Mangalore, Karnataka, India.

Corresponding Author: Sandhya M K, Department of Anesthesiology, Kanachur institute of medical Sciences, Mangalore, Karnataka, India.

Citation this Article: Sandhya M K, Kiran Kumar, Sambhram Shenoy, “Surgically Placed Subcostal Transversus Abdominis Plane Catheter Infusion for Post Operative Analgesia in Upper Abdomen Surgeries - A Case Series”, IJMSIR- November - 2022, Vol – 7, Issue - 6, P. No. 23 – 26.

Type of Publication: Case Report

Conflicts of Interest: Nil

Abstract

Pain management is an integral part of enhanced recovery after surgery. Epidural anaesthesia is considered gold standard for post operative pain relief in abdominal surgeries. However, hypotension and coagulopathies limit the use of epidural analgesia in critically ill patients. Transverse abdominus plane block has gained popularity over last two decades and has been used as a part of multimodal anaesthesia to reduce post operative opioid consumption. Even though TAP block does not provide relief from visceral pain previous studies have shown that TAP catheter infusion is as efficacious as epidural infusion in patients undergoing upper and lower abdominal surgeries. ^(1,2) Unavailability of ultrasound in OT in peripheral hospitals limits the placement of catheter. Placement of catheter under ultrasound requires a higher level of skill moreover distorted anatomy due to surgery, dressings, air in the tissues, oedema, obesity makes identification of the anatomy more difficult. Surgically placed catheter is an excellent alternative. Placement of catheter under direct vision ensures

deposition of the local anaesthetic in the right plane. We present a case series where TAP catheter was surgically placed after dissecting the plane between Transversus abdominis and internal oblique, transversus abdominis and Rectus sheath. The point of entry was lateral to the line semilunaris and the catheter was directed medially. Bupivacaine 0.125% bolus dose 20 millilitres followed by infusion at the rate of five to eight ml/hr was started after placement of the catheter. All patients had good pain relief; the catheter was removed after forty-eight hours.

Keywords: subcostal TAP infusion, surgically placed, TAP catheter.

Introduction

Transversus abdominal plane block has been used for post operative pain relief in abdominal surgeries. Previous studies have shown that TAP catheter infusion is as efficacious as epidural infusion in patients undergoing upper and lower abdominal surgeries. ^(1,2) Unavailability of ultrasound in OT in peripheral hospitals limits the placement of catheter, moreover ultrasound

guided placement of catheter requires a higher level of skill and is time consuming. Surgically placed TAP catheter is an excellent alternative as the catheter is placed under direct vision and therefore ensures deposition of the local anaesthetic in the right plane.

Case Series

This case series includes five patients posted for upper abdominal surgeries with subcostal incisions. Subcostal TAP catheter was surgically placed in all patients for post operative pain relief [Table 1]. After obtaining written informed consent, patients were shifted to OT. General anaesthesia was induced as per institutional guidelines with propofol, fentanyl and vecuronium, endotracheal intubation was performed. Fentanyl and paracetamol intravenous infusion was used for intraoperative analgesia. All patients were maintained on oxygen air and sevoflurane.

TAP Catheter insertion: In all patients Transversus abdominis plane catheter was placed by the surgeon before closure. Plane above the transversus abdominis and internal oblique, rectus abdominis and transverse abdominis, Linea semilunaris was dissected. 18-gauge Touhy's needle was introduced through the internal oblique aponeurosis and directed upwards towards the skin (Figure A). Epidural catheter was threaded through the needle and needle was removed, four to five cm of the catheter was left in the plane above transverse abdominis and catheter was directed medially. Abdomen was closed in layers. After closure Bupivacaine 0.125% bolus dose 20 ml was given through the TAP catheter and infusion was started at the rate of 5 to 8 ml per hour. All patients were reversed neostigmine and glycopyrrolate and extubated after eye opening was present. Patients were shifted to PACU. All patients received paracetamol 20mg/kg as IV infusion 8th hourly. Tramadol 2mg/kg IV was given when VAS>3. All patients had excellent

analgesia Patient 1, 2 and 5 did not require any rescue analgesia and patient 3 and 5 required 2 doses of tramadol. Tap catheter was removed after 48 hours. Patient 1 developed collection which settled with antibiotics none of the other patients developed any catheter related complications.

Discussion

Pain management is an integral part of enhanced recovery after surgery. Epidural anaesthesia is considered gold standard for post operate pain relief in abdominal surgeries. However, hypotension and coagulopathies limit the use of epidural analgesia in critically ill patients. Transversus abdominis plane block has gained popularity over last two decades and has been used as a part of multimodal anaesthesia to reduce post operative opioid consumption. Placement of catheter under ultrasound requires a higher level of skill moreover distorted anatomy due to surgery, dressings, air in the tissues, oedema, obesity makes identification of the anatomy more difficult. Surgically placed catheter is an excellent alternative. Transversus abdominis plane compartment is an anatomical plane between the internal oblique and transversus abdominis that contains T6 to L1 thoracolumbar nerves.^[3,4,5] The anterolateral abdominal wall is innervated mainly by the anterior rami of the thoracolumbar spinal nerves [T6 to T11] as intercostal [T6 to L1], subcostal[T12] and ilioinguinal and iliohypogastric nerves[L1]^[3,4,5]. These branches further communicate in the anterior abdominal wall at multiple locations.^[4] TAP block was first described by Rafi in 2001 as a landmark technique as a field block involved deposition of local anaesthetic in the triangle of Petit.^[4,5] The term transversus abdominal plane block was first introduced by O'Donnell^[7]. Ultrasound guided TAP block was first described by Hebbard et al^[6,7]. The nomenclature regarding approaches still remains

controversial.^[7] Posterior, lateral, subcostal approaches have been described.^[7] In the posterior approach local anaesthetic is deposited in TAP plane in lumbar triangle of petit.^[7] Lateral approach targets the TAP plane in the lateral abdominal wall between the mid axillary and anterior axillary lines.^[7] Ultrasound guided four quadrant TAP block where local anaesthetic is injected into bilateral lateral TAP plane and subcostal plane has also been described.^[9] The posterior and lateral TAP block provides consistent blockade of T10-L1 abdominal dermatomes and works well for lower abdominal surgeries. If analgesia over supraumbilical wall is required, subcostal, oblique subcostal or dual TAP blocks are recommended.^[4,9] Subcostal TAP block was described by Hebbard involves injection of local anaesthetic into the TAP plane lateral to the Linea semilunaris immediately inferior and parallel to the costal margin^[5] Oblique subcostal TAP block is a modified version of Subcostal TAP block where under ultrasound guidance needle is inserted medial to Linea semilunaris then directed laterally after hydro dissection along a line from xyphoid sternum towards the anterior part of iliac crest.^[5] Tap block with multiple punctures along oblique subcostal line has been described.^[8] In SCTAP local anaesthetic may be injected in TAP plane medial or lateral to semilunaris.^[9] Injection medial to the semilunaris may miss nerves that have entered rectus abdominus lateral to the injection. A single shot subcostal TAP block 5-to-10-centimetre lateral to the umbilicus covered T9 to L1 dermatome.^[6] A continuous TAP block using a catheter with more extensive holes may produce a wider spread of local anaesthetic and better analgesia.^[4] Although ultrasound guided TAP is considered a low-risk procedure liver lacerations have been reported.^[4] Other complications include Abdominal wall hematoma, bowel or diaphragm perforation,

vascular injury and local anaesthetic toxicity. Surgically placed TAP catheter is an alternative, as the catheter is placed under vision ensures spread of local anaesthetic in the right plane. Local anaesthetic volume from 5 to 15 ml^[1,2] have been used previously, in our cases we have used volume as low as 5 ml. More studies are required to compare the analgesic efficacy and failure rate of ultrasound guided transverse abdominal plane catheter with surgically placed catheter, compare different approaches to catheter placement and the volume of local anaesthetic infusion

Figures and tables

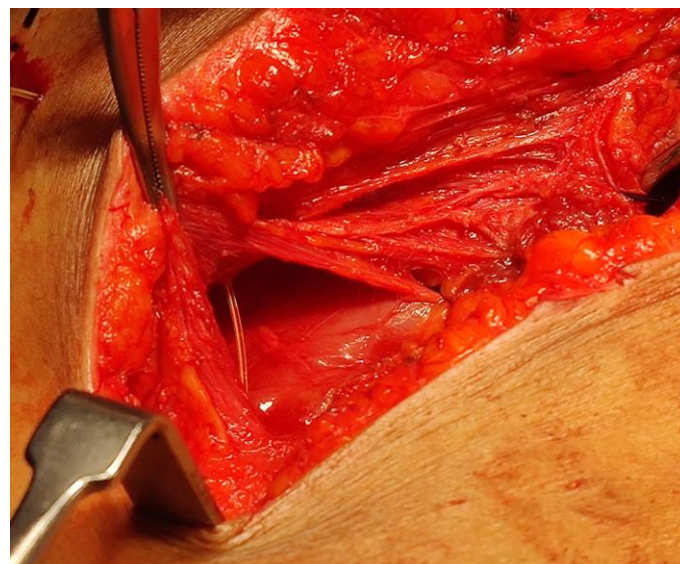


Figure 1

Table 1

Case	Age/sex	Diagnosis	Surgeries	Comorbidities
1	41/F	Splenic abscess	Splenectomy	Sepsis
2	58/M	Gangrenous gall bladder	Open Cholecystectomy	Diabetes Mellitus
3	42/M	Cholelithiasis	Open cholecystectomy	-

4	50/F	Acute Cholecystitis	Lap converted to open cholecystectomy	Hypertension
5	47/F	Cholelithiasis	Lap converted to open cholecystectomy	-

References

1. Niraj G, Kelkar A, Jeyapalan I, Graff-Baker P, Williams O, Darbar A, Maheshwaran A, Powell R. Comparison of analgesic efficacy of subcostal transversus abdominis plane blocks with epidural analgesia following upper abdominal surgery. *Anaesthesia*. 2011 Jun; 66 [6] :465-71.
2. Regmi S, Srinivasan S, Badhe AS, Satya Prakash M, Adi Narayanan S, Mohan VK. Comparison of analgesic efficacy of continuous bilateral transversus abdominis plane catheter infusion with that of lumbar epidural for postoperative analgesia in patients undergoing lower abdominal surgeries. *Indian J Anaesth*. 2019 Jun; 63 [6]: 462-468.
3. Khurana J, Ip V, Todd G, Sondekoppam RV. How I do it: Surgically inserted transversus abdominis plane [TAP] catheters for flank incisions. *Can J Urol*. 2018 Dec; 25 [6]: 9623-9626.
4. Tsai HC, Yoshida T, Chuang TY, Yang SF, Chang CC, Yao HY, Tai YT, Lin JA, Chen KY. Transversus Abdominis Plane Block: An Updated Review of Anatomy and Techniques. *Biomed Res Int*. 2017; 2017: 828 4363
5. Hebbard PD, Barrington MJ, Vasey C. Ultrasound-guided continuous oblique subcostal transversus abdominis plane blockade: description of anatomy and clinical technique. *Reg Anaesth Pain Med*. 2010 Sep-Oct;35[5]:436-41.

6. Mitchell AU, Torup H, Hansen EG, Petersen PL, Mathiesen O, Dahl JB, Rosenberg J, Møller AM. Effective dermatomal blockade after subcostal transversus abdominis plane block. *Dan Med J*. 2012 Mar;59[3]: A4404.
7. Tran DQ, Bravo D, Leurcharusmee P, Neal JM. Transversus Abdominis Plane Block: A Narrative Review. *Anaesthesiology*. 2019 Nov;131[5]:1166-1190
8. Mukherjee A, Guha Biswas R, Kshirsagar S, Rupert E. Ultrasound guided oblique subcostal transversus abdominis plane block: An observational study on a new and promising analgesic technique. *Indian J Anaesth*. 2016 Apr;60[4]:284-6.
9. Soliz JM, Lipski I, Hancher-Hodges S, Speer BB, Pop at K. Subcostal Transverse Abdominis Plane Block for Acute Pain Management: A Review. *Anaesth Pain Med*. 2017 Oct 20;7[5]:e12923.
10. Carney J, Finnerty O, Rauf J, Bergin D, Laffey JG, Mc Donnell JG. Studies on the spread of local anaesthetic solution in transversus abdominis plane blocks. *Anaesthesia*. 2011 Nov; 66 [11]: 1023-30.