

**Anterior approach for sciatic nerve localization - A novel observational study utilizing sonoanatomical landmarks**

<sup>1</sup>Dr. Rupali, M.B.B.S, D.N.B., A.O.R.A. Fellow/ Senior Resident in Department of Anaesthesiology, DMCH, Ludhiana

<sup>2</sup>Dr. Richa Jain, M. B. B. S., M. D., Associate Professor in Department of Anaesthesiology, DMCH, Ludhiana.

<sup>3</sup>Dr. M. Rupinder Singh, M.B.B.S, M.D, Professor in Department of Anaesthesiology, DMCH, Ludhiana.

<sup>4</sup>Dr. Anju Grewal, M.B.B.S, M.D., Professor and Head in Department of Anaesthesiology, DMCH, Ludhiana.

<sup>5</sup>Dr. Gaurav, M.B.B.S., D. N. B. T, Fortis hospital, Shalimar Bagh, New Delhi.

<sup>6</sup>Arshdeep Singh, Medical Student, Adesh Institute of Medical Sciences, Bathinda, Punjab.

**Corresponding Author:** Dr. Rupali, M.B.B.S, D.N.B., A.O.R.A. Fellow/Senior Resident in Department of Anaesthesiology DMCH Ludhiana.

**Citation this Article:** Dr. Rupali, Dr. Richa Jain, Dr. M. Rupinder Singh, Dr. Anju Grewal, Dr. Gaurav, Arshdeep Singh, “Anterior approach for sciatic nerve localization - A novel observational study utilizing sonoanatomical landmarks”, IJMSIR- July - 2022, Vol – 7, Issue - 4, P. No. 131 – 136.

**Type of Publication:** Original Research Article

**Conflicts of Interest:** Nil

**Abstract**

**Background:** Anterior approach to sciatic nerve block has been an underutilized technique due to the technical difficulties and lack of accurate landmarks to guide the localization of nerve. This prospective observational study was planned to evaluate the sonoanatomical relationship of sciatic nerve with femoral neurovascular complex and femoral shaft by anterior approach for easy identification.

**Methods and materials:** After ethics committee approval and written informed consent Sono anatomy of sciatic nerve in anteromedial thigh was observed in 30 ASA I-III patients. Measurements of distance between sciatic nerve, femoral shaft and femoral neurovascular complex were taken. Surface landmark for probe positioning was also noted.

**Results:** We observed that sciatic nerve was consistently located in a triangular arrangement with femoral shaft and femoral neurovascular complex. Distance of sciatic

nerve from femoral shaft located superiolaterally was  $43.4 \pm 12$ mm. Distance of sciatic nerve from femoral neurovascular complex located superiorly was  $44.8 \pm 11.4$  mm. Distance between femoral shaft and femoral neurovascular complex was  $39.1 \pm 9.4$  mm and distance of ultrasound probe placement for optimal visualization of sciatic nerve from inguinal crease was  $16.7 \pm 2.9$  cm.

**Conclusion:** We propose a new and more distal sonoanatomical landmarks for ultrasound guided approach to anterior sciatic nerve block which consistently localizes the sciatic nerve in relation to femoral shaft and femoral neurovascular complex and can be easily performed in all patients in supine position.

**Keywords:** Sciatic nerve block, sonoanatomical landmarks, anterior approach, femoral vessels, femur, ultrasound guided.

**Introduction**

Ultrasound imaging is a useful tool to identify the sciatic nerve (SN) at different levels along its course [1,2,3].

The consistent anatomical relationship between the SN and the neighbouring bony structures i.e., ischial spine, ischial tuberosity and lesser trochanter have been described as valuable markers for localization of SN [4]. The anterior approach aims to target the SN adjacent to the lesser trochanter of the femoral shaft in the proximal thigh [7,8]. In a volunteer study using ultrasound directly over the femoral shaft with leg in conventional supine neutral position, authors could not visualize SN at lesser trochanter level [4]. However, with external rotation of hip, the SN was visible at the same level, deep to the adductor magnus muscle with femoral neurovascular bundle far lateral to it. Thus, we proposed this study to evaluate the relationship of SN more distally in the anterior compartment of the thigh in relation to the femoral shaft and femoral neurovascular complex with leg in supine neutral position. This approach would possibly aid in defining the distance, desired site; and more consistent and reliable landmarks to identify SN during real time visualization.

### Material and methods

This prospective observational clinical study was conducted after approval by Institutional Ethics Committee and CTRI registration (CTRI/ 2022 /01/ 039875) on a total of ASA I-III thirty patients aged above 16 years.

After taking a written informed consent, patient was placed in supine position with leg in neutral position and scanning was done with low frequency (2-5 MHz) curvilinear ultrasound probe [ Edge II Sonosite, USA (portable)] on anteromedial thigh with pointer lateral to find an optimal view of the SN, femoral neurovascular complex and femoral shaft in one scan.

Scanning was started from 8 cm below inguinal crease and probe was moved along the anteromedial direction

distally in the thigh till the point where muscles of adductor compartment were visualized. The SN was identified as a bright hyperechoic oval structure under the adductor magnus, just medial and deep to femoral shaft. In this view, the femoral neurovascular complex was also visualized just beneath the sartorius muscle.

Once visualized, distance between all three structures and distance of ultrasound probe from midpoint of inguinal crease were measured and recorded. Also, their anatomical correlation observed.

Distance 'A' is distance of sciatic nerve from femoral shaft (mm). Distance 'B' is distance of sciatic nerve from femoral neurovascular complex (mm). Distance 'C' is distance between femoral shaft and femoral neurovascular complex (mm). Distance 'D' is distance of ultrasound probe placement from inguinal crease (cm), (Figure1)

Our primary outcome was to observe the sonoanatomical relationship of SN with femoral neurovascular complex and femoral shaft and secondary outcome was to find an optimal probe distance from inguinal crease.

The sample size was calculated to know the distance D among adults at 95% confidence interval, with margin of error 1.5 and taking standard deviation of distance D to be 4 cm based on the experience. Assuming  $\alpha$ -error (significance) of 0.05 and power (1-  $\beta$ ) of 80%, the effective sample size on the basis of distance D came out to be 27.

Statistical analysis: Patient demographics and all the distances measured were described in terms mean  $\pm$  standard deviation ( $\pm$  SD). Cronbach's alpha test was used to determine the consistency of correlation among the distances. A reliability coefficient of 0.725 or higher was considered statistically significant. All statistical calculations were done using (Statistical Package for the

Social Science) SPSS 21 version (SPSS Inc., Chicago, IL, USA) statistical program for Microsoft Windows.

## Results

The scanning was performed on 30 (11 females and 19 males) ASA I - III patients aged 17-86 yr (mean of 45.2) with mean height  $167.73 \pm 9.10$  cm, mean weight  $75 \pm 14.54$  kg and BMI of  $26.44$  kg/m<sup>2</sup> respectively. [Table 1]

Table 2 shows mean distances of sciatic nerve from femoral neurovascular complex and femoral shaft, mean distance between femoral shaft and femoral neurovascular complex and distance of ultra sound probe placement from inguinal crease (cm)

On scanning a consistent triangular topographical relationship was observed among sciatic nerve, femoral shaft and femoral neurovascular complex. [Figure 2]

The correlation between distance A, B and C is significant (Cronbach's  $\alpha = .765$ ) hence SN, femoral shaft and femoral neurovascular bundle will be found in consistent triangular correlation as described. [Table 3]

Differences in the observed measurements between males and females were compared and shown in table 4. Distance of sciatic nerve from femoral shaft was statistically different between males and females.

## Discussion

We observed that on scanning the anteromedial thigh, SN was consistently located deep to adductor magnus at distance of  $16.7 \pm 2.9$  cm below the inguinal crease. In relation to SN, femoral neurovascular complex was located superiorly at distance of  $44.8 \pm 11.4$  mm and femoral shaft located superiolaterally at distance of  $43.4 \pm 12.0$  mm hence, forming a triangular relationship. This consistent arrangement of all three structures could help in better localization of SN which lies deep to the muscles in anteromedial compartment and could be

extrapolated in clinical practice in trauma patients for providing perioperative pain relief where lateral, lithotomy[5] or prone[6] positioning may not be feasible.

The landmark based anterior approaches were described by Beck (7) and Chelly Delaunay [8] to block the sciatic nerve. Both of these techniques used anatomic surface landmarks (greater trochanter and lesser trochanter respectively) and were performed in neutral leg position. However, these approaches have been associated with technical difficulties which can now be overcome by ultrasound guidance [1,2,3].

In a clinical and imaging study, authors concluded that inguinal crease and femoral artery are reliable and effective anatomic landmarks for anterior approach to sciatic nerve block but found that external rotation is required for optimal results at lesser trochanter level. [9,4] Considering the fact that external rotation of leg required for this approach might be extremely painful for patients with lower extremity fractures, we decided to use neutral leg position with inguinal crease as surface landmark and femoral neurovascular complex along with femoral shaft as sonoanatomical landmarks for localization of sciatic nerve.

Chan [4] evaluated the usefulness of low frequency ultrasound probe to identify the sciatic nerve in proximal thigh by anterior approach and provided high quality images. With the limb semi flexed and externally rotated at the lesser trochanter level, they scanned approximately 8 cm distal to the inguinal crease in transverse orientation on the medial side of the thigh and found hyperechoic sciatic nerve posterior and medial to the lesser trochanter. However, while performing the procedure their needle path was obstructed by lesser trochanter.

Similar observations were also made by Ericksen [10] in an imaging study where he concluded that the position of

the sciatic nerve relative to lesser trochanter made it inaccessible from anterior approach. Further on needle insertion 4 cm below lesser trochanter was found to be a more direct anatomical approach to the anterior sciatic nerve block. Thus, we placed the probe more distal in the thigh so as to allow unobstructed path to the needle.

Also in a cadaver study Vloka [11] confirmed that lesser trochanter often obstructs the path of needle to the SN in anterior approach in neutral leg position however the needle passage was facilitated after internal rotation of leg by 45°. On the basis of observations made by Volka et al, Chantzi [12] and team performed ultrasound guided anterior sciatic nerve block in 18 obese patients with successful localization of SN with one needle attempt in all patients.

Since all the investigators were unsuccessful in optimal visualization and ultrasound guided performance of the SN block in neutral leg position, the sonoanatomical landmarks described in our study may prove to be of significant utility.

Ours is an observational study where we only defined the consistent and reliable sonoanatomical landmarks for localization of SN, however its application for real time ultrasound guided anterior sciatic nerve block needs to be evaluated.

### Conclusion

Ultrasound can reliably and consistently define sciatic nerve location. We describe a novel more distal approach to anterior sciatic nerve block which consistently localizes the sciatic nerve in relation to femoral shaft and femoral neurovascular complex and can be easily performed in all patients in supine position. This technique negates the technical difficulties of previously described classical approaches and provides an easy alternative to lateral and prone approaches of sciatic

nerve block. Future clinical studies are needed to further validate these results.

### References

1. Marhofer P, Chan VW. Ultrasound-guided regional anesthesia: current concepts and future trends. *Anesth Analg*. 2007; 104:1265-9.
2. Marhofer P, Greher M, Kapral S. Ultrasound guidance in regional anesthesia. *Br J Anaesth* 2005; 94:7–17.
3. Karmakar MK, Kwok WH. Ultrasound-guided regional anesthesia. In *A practice of anesthesia for infants and children*. Elsevier. 2019:988-1022.
4. Chan VWS, Nova H, Abbas S, McCarney CJL, et al. Ultrasound examination and localization of the sciatic nerve: a volunteer study. *Anesthesiology* 2006; 104:309–14.
5. Raj PP, Parks RI, Watson TD, Jenkins MT. A new single-position supine approach to sciatic-femoral nerve block. *Anesth Analg*. 1975; 54:489-93.
6. Labat G. *Regional anesthesia: its technique and clinical applications*. 2nd ed. Philadelphia, PA: WB Saunders, 1924: 45–55.
7. Beck G. Anterior approach to sciatic nerve block. *Anesthesiology*. 1963; 24:222-4.
8. Chelly JE, Delaunay. A new anterior approach to the sciatic nerve block. *Anesthesiology* 1999; 91:1655–60.
9. Van Elstraete AC, Poey C, Lebrun T, Pasture au F. New landmarks for the anterior approach to the sciatic nerve block: imaging and clinical study. *Anesthesia & Analgesia*. 2002; 95:214-8.
10. Ericksen, Marty L. MD; Swenson, Jeffrey D. MD; Pace, Nathan L. MD, MS *tat the Anatomic Relationship of the Sciatic Nerve to the Lesser Trochanter: Implications for Anterior Sciatic Nerve Block*. *Anesth Analg*. 2002; 95:1071-1074

11. Vloka JD, Hadžic A, April E, Thys DM. Anterior approach to the sciatic nerve block: the effects of leg rotation. *Anesth Analg*. 2001; 92:460-2.

nerve at the anterior thigh in obese patients. *Acta anesthesiologica scandinavica*. 200

12. Chantzi C, Saran teas T, Zogogiannis J, Alevi Zou N, Dimitriou V. Ultrasound examination of the sciatic

**Legend Tables**

Table1: Patients’ demographics Data described as mean±SD

	Male (n=19)	Female (n=11)
Age (yrs)	57.09±18.95.	38.37±19.65
Height (cm)	173.74±5.14	157.36±2.46
Weight (kg)	80.95±13.04	64.73±11.12
BMI (kg/m <sup>2</sup> )	26.68±3.43	26.03±4.03
ASA I, II, III	1,7,3	11,5,3

Table 2: Mean distances between SN, femoral neurovascular complex, femoral shaft and inguinal crease.

	N	Mean	SD
Distance E A (mm)	30	43.4	12.0
Distance B (mm)	30	44.8	11.4
Distance C (mm)	30	39.1	9.4
Distance D (cm)	30	16.7	2.9

Table 3: Correlation between all 4 distances

Item-Total Statistics						
	Scale Mean if Item Deleted	Scale Variance if Item Deleted	Corrected Item-Total Correlation	Squared Multiple Correlation	Cronbach's Alpha if Item Deleted	
DISTANCE A	100.62	362.157	.672	.525	.561	
DISTANCE B	99.24	377.270	.685	.497	.547	
DISTANCE C	104.93	516.786	.488	.250	.679	
DISTANCE D	127.30	738.583	.414	.217	.765*	

	Intraclass Correlation	95% Confidence Interval	
		Lower Bound	Upper Bound
Average Measures	.725 <sup>c</sup>	.520	.857

\*cronbach's alpha score >0.725 considered statistically significant.

Figure 1: Cross-section of thigh showing the Sciatic nerve (SN), femoral shaft(FS) and femoral neurovascular complex(FNVC), VM- vastus medialis, VI- vastus intermedius, VL- vastus lateralis, RF- rectus femoris, Sa- sartorius, AL- adductor longus, AM- adductor magnus, BF- biceps femoris (short and long), ST- semitendinosus, SM- semimembranosus, A- distance of SN from FS, B- distance of SN from FNVC, C- distance of FS from FNVC.

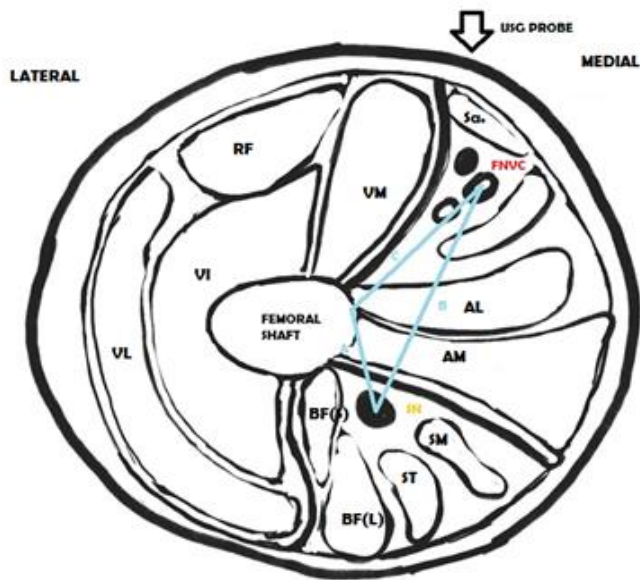


Figure 2: Ultra sound image of Sciatic nerve in relation to femoral shaft and femoral neurovascular complex. SN- Sciatic nerve, FNVC – femoral neurovascular complex, FS- femoral shaft. A- distance of SN from FS, B- distance of SN from FNVC, C- distance of FS from FNVC.

