

Gallbladder Carcinoma in a Young Female - A rare presentation

¹Dr. Rakhi K. Suryawanshi, Department of Pathology, NKP Salve Institute of Medical Sciences and RC, Hingna, Nagpur.

²Dr. Sadhana Mahore, Associate Professor, Department of Pathology, NKP Salve Institute of Medical Sciences and RC, Hingna, Nagpur.

³Dr. Kalpana Bothale, Associate Professor, Department of Pathology, NKP Salve Institute of Medical Sciences and RC, Hingna, Nagpur.

⁴Dr. Sabiha Maimoom, Associate Professor and HOD, Department of Pathology, NKP Salve Institute of Medical Sciences and RC, Hingna, Nagpur.

⁵Dr. Vidula Gowardhan, Lecturer, Department of Pathology, NKP Salve Institute of Medical Sciences and RC, Hingna, Nagpur.

Corresponding Author: Dr. Rakhi K. Suryawanshi, Department of Pathology, NKP Salve Institute of Medical Sciences and RC, Hingna, Nagpur.

Citation this Article: Dr. Rakhi K. Suryawanshi, Dr. Sadhana Mahore, Dr. Kalpana Bothale, Dr. Sabiha Maimoom, Dr. Vidula Gowardhan, “Gallbladder Carcinoma in a Young Female - A rare presentation”, IJMSIR- June - 2022, Vol – 7, Issue - 3, P. No. 80 – 84.

Type of Publication: Case Report

Conflicts of Interest: Nil

Abstract

Gallbladder carcinoma is very rare in young adults (< 30 years of age). The purpose of this report is to present an unusual case of gallbladder carcinoma in a young female with acute clinical presentation. A 23 years female presented with pain in abdomen and vomiting since two days who was further investigated and clinically diagnosed as a case of cholecystitis. However, adenocarcinoma was the postoperative histopathological diagnosis of cholecystectomy.

Keywords: Carcinoma in young female, Cholecystectomy, Gallbladder carcinoma in young, ICBC.

Abbreviations: GB-Gallbladder, GBC-Gallbladder carcinoma, ICBC-incidental gallbladder carcinoma.

Introduction

Gallbladder carcinoma is the most common and aggressive biliary tract malignancy worldwide which manifests as either diffuse thickening of the GB wall or as a GB mass arising from the fundus, neck or body of the GB ^(1, 2). Lack of sensitive screening tests for early detection results in delayed diagnosis at advanced stage and so the prognosis is poor ⁽³⁾.

Gallbladder carcinoma tends to increase with advancing age (median age being 67 years), as the malignancy takes decades to develop ⁽⁴⁾. Women are affected two to six times more commonly than men ⁽⁵⁾. There is marked geographical and ethnic variations in the incidence of this malignancy ⁽⁶⁾. India is a high incidence area for GBC ⁽²⁾. The Surveillance, Epidemiology, and End Results (SEER) database from the US from 2015 reveals that

age-adjusted incidence rates (per 100,000) in 2015 rose from 0.2 for those aged 20-49 years, to 1.6 for those aged 50-64 years, to 4.3 for those aged 65-74 years, and to 8.1 for individuals aged 75 years and older. This corresponded with mortality rates (per 100,000), which increased from 0.1 for those aged 20-49 years, to 0.7 for those aged 50-64 years and to 2.1 for those aged 65-74 years⁽⁷⁾.

Risk factors of GBC include cholelithiasis, calcified gallbladder wall, adenomatous polyp, obesity, estrogens, choledochal cyst and chemical carcinogens⁽⁸⁾.

In lifetime of women, they are exposed to higher levels of estrogens and progesterone mainly during pregnancies. In comparison to western developed countries, Indian women are younger in age at the time of marriage, younger in age at time of 1st pregnancy and have a higher number of pregnancies, also are less educated, less accessible to economic resources, nutrition and poor accessibility to medical care which categorize them in socio-economically poor strata. Less nutrition access causes micronutrient deficiencies which promote carcinogenesis⁽²⁾.

In most patients, the tumour is diagnosed by the pathologist after a routine cholecystectomy for a benign disease and is termed "incidental or occult gallbladder carcinoma" (IGBC)⁽⁹⁾. It is also known as occult/inapparent/missed GBCs. The incidence of IGBC is reported to be 0.2%–2.1%⁽⁸⁾. The aetiology for IGBC remains same as other GBC.

Our case is rare example of GBC since it was presented in young female otherwise it is a disease of elderly. Also the clinical presentation of the patient and radiological findings did not suggest malignancy till histopathological diagnosis as adenocarcinoma was given, so it can also be included in IGBC.

Case report

A 23 years, thin built female from poor socioeconomic strata, married at 18 years and mother of two presented with pain in abdomen and vomiting since two days. On clinical examination tenderness in right hypochondrium was present.

She was investigated thoroughly. CBC was within normal limits.

Total Protein: 6.70 gm/dl, Albumin: 3.20gm/dl, Globulin: 3.50 gm/dl, A/G Ratio: 0.91 (Altered ratio)

PT-Prothrombin Time: 14 (Slightly raised), INR: 1.0, Index: 89.66

LFT (Liver Function Test) : Bilirubin (total) : 5.41 mg/dl , conjugated : 3.73 mg/dl , unconjugated : 1.60 mg/dl.

AST/ SGOT: 72.00 U/L, ALT/SGPT: 217.00 U/L, Alkaline Phosphates: 209.00 U/L,

Serum amylase: 37.00 U/L, Serum lipase : 59.00 U/L.

KFT (Kidney Function Test) : Urea : 16.00 mg/dl , Serum creatinine : 0.53 mg/dl, Sodium : 137 mEq/L, Potassium : 3.6 mEq/L.

Tumor markers CEA and CA 19-9 were not done.

USG was suggestive of cholelithiasis (Gallbladder is distended with single conglomerated hyperechoic focus giving post acoustic shadow noted within the lumen).

MRI showed cholelithiasis with choledocholithiasis with dilated cystic duct and common hepatic duct.

So considering radiological findings, clinical diagnosis of e/o empyema GB with cholelithiasis with impacted cystic duct stone was made.

Patient was taken for laparoscopic surgery. However, it was converted to open surgery as there was difficulty to remove impacted stone in the cystic duct.

Post-operative examination of cholecystectomy specimen revealed approximately 7x3.5x1.2cm smooth and pinkish gallbladder. Gallbladder wall was mostly soft in consistency, however small firm yellowish area

measuring approximately 1.8 x 1.5 x 0.5 cm was seen in the neck near the cystic duct. Single yellowish (cholesterol) multifaceted stone is identified measuring approximately 0.5x0.3x0.3cm.

Sections taken from various areas revealed necrotic, ulcerated, flattened mucosa lined by columnar epithelium showing dysplastic changes with scattered mononuclear inflammatory infiltrate. Sections taken from the yellowish firm areas revealed the glands penetrating the muscular layer and infiltrating up to the serosal surface with extracellular mucin at places. Perineural invasion was seen. There was no extension beyond the serosal surface. There was no lymph vascular invasion and surgical margins were free.

Histological diagnosis of cholelithiasis with chronic cholecystitis with well differentiated adenocarcinoma of gallbladder with Perineural invasion was given.

TNM Staging: According to 7thAJCC gallbladder carcinoma: T2 N0 M0 Stage II.

Patient was advised 4 chemotherapy cycles with gemcitabine and oxalipatin. However, she completed only 1 cycle due to financial constraints and she passed away 6 months after the surgery.

Discussion

The presence of gallstones causes chronic irritation and local production of carcinogens such as secondary bile acids which leads to sequential development of metaplasia/hyperplasia, dysplasia and finally carcinoma (7).

Pathogenesis of gallbladder carcinoma is unclear because of additive multiple risk factors (10). So though GBC is more common in elderly, a high index of suspicion is required to diagnose it in younger patients in high incidence areas (2).

Gallstones are easiest to identify and also easiest target for preventing GBC among all the risk factors.

Therefore, prophylactic cholecystectomy may be done in patients with gallstone who are at high risk for GBC (2).

And therefore critical gross examination of gallbladder is essential for proper timely diagnosis of carcinoma of gallbladder.

GBC is rare occurrence in young patients < 30 years and that too more commonly reported in males (10, 11, 12, 13).

Our case is rare example of GBC because of young age of female patient who was clinically diagnosed as cholelithiasis with acute cholecystitis and then histopathologically diagnosed as adenocarcinoma.

Due to low socioeconomic status of patients, mostly in developing countries early diagnostic markers and new researches which are happening for the early diagnosis of GBC are not affordable. Therefore, keeping high index of suspicion of malignancy proper gross and histopathological examination from firm or thickened areas of each cholecystectomy specimen is very important.

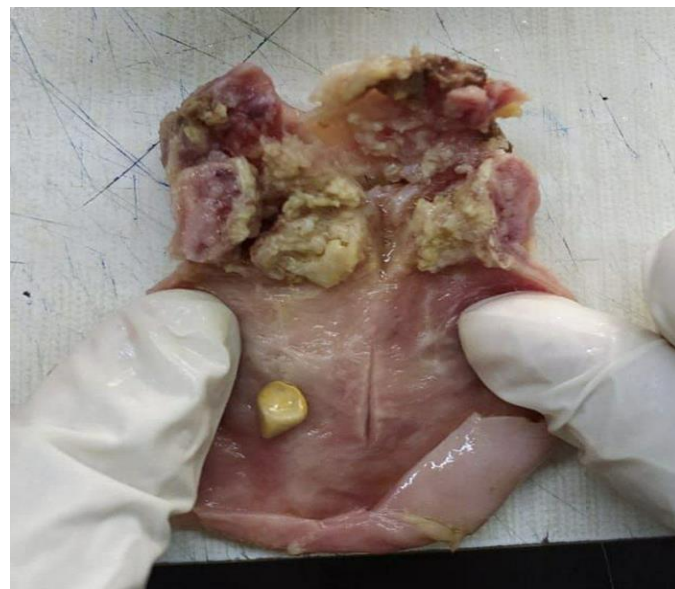


Figure 1: Cut open specimen of gallbladder with single multifaceted stone and firm thickened area near the neck.

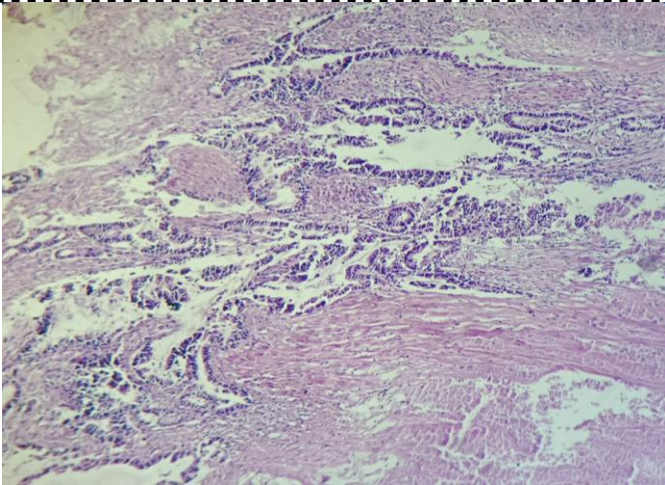


Figure 2: Scanner view

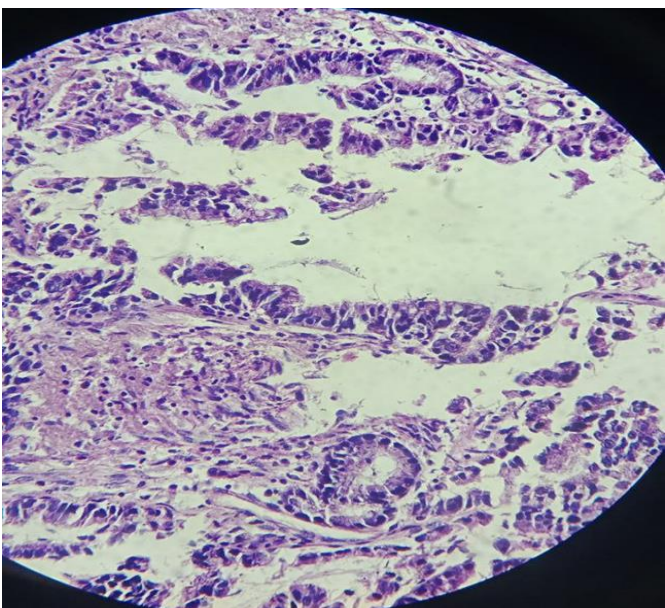


Figure 3: Low power view

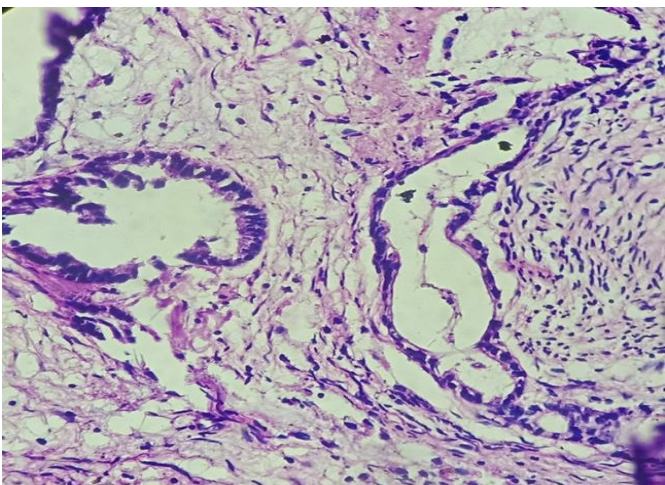


Figure 4: Low power view

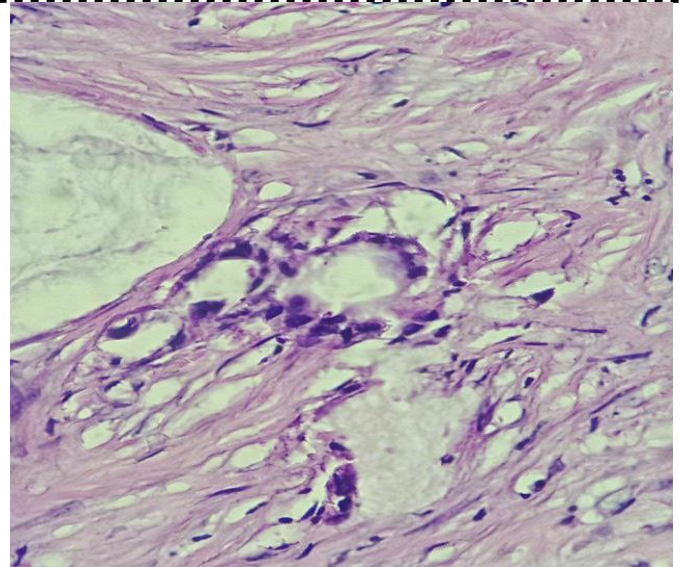


Figure 5: Perineural invasion by tumor is seen.

Inset =High power view: Nuclear atypia and extracellular mucin pool.

Conclusions

Gallbladder carcinoma in younger age group is a rare occurrence but is to be suspected in patients with complaints of cholelithiasis and histopathological examination of the cholecystectomy specimens has to be carefully carried out with high index of suspicion.

References

1. Zhu AX, Hong TS, Hezel AF, Kooby DA. Current management of gallbladder carcinoma. *The oncologist*. 2010 Feb;15(2):168-81.
2. Dutta U, Bush N, Kalsi D, Popli P, Kapoor VK. Epidemiology of gallbladder cancer in India. *Chin Clin Oncol*. 2019 Aug 1;8(4):33.
3. Dutta U. Gallbladder cancer: can newer insights improve the outcome?. *Journal of gastroenterology and hepatology*. 2012 Apr;27(4):642-53.
4. Hundal R, Shaffer EA. Gallbladder cancer: epidemiology and outcome. *Clinical epidemiology*. 2014;6:99.
5. Duffy A, Capanu M, Abou-Alfa GK, Huitzil D, Jarnagin W, Fong Y, D'Angelica M, Dematteo RP,

- Blumgart LH, O'Reilly EM. Gallbladder cancer (GBC): 10-year experience at memorial Sloan-Kettering cancer centre (MSKCC). *Journal of surgical oncology*. 2008 Dec 1;98(7):485-9.
6. Randi G, Franceschi S, La Vecchia C. Gallbladder cancer worldwide: geographical distribution and risk factors. *International journal of cancer*. 2006 Apr 1;118(7):1591-602.
7. Rawla P, Sunkara T, Thandra KC, Barsouk A. Epidemiology of gallbladder cancer. *Clinical and experimental hepatology*. 2019 May;5(2):93.
8. Jha V, Sharma P, Mandal KA. Incidental gallbladder carcinoma: Utility of histopathological evaluation of routine cholecystectomy specimens. *South Asian journal of cancer*. 2018 Jan;7(01):21-3.
9. Goetze TO. Gallbladder carcinoma: prognostic factors and therapeutic options. *World journal of gastroenterology*. 2015 Nov 21;21(43):12211.
10. Haff RC, Andrassy RJ, LeGrand DR, Ratner IA. Gallbladder disease in the young male. *The American Journal of Surgery*. 1976 Feb 1;131(2):232-4.
11. Tanaka S, Kubota D, Lee SH, Oba K, Yamamoto T, Ikebe T, Kubo S, Matsuyama M. Latent gallbladder carcinoma in a young adult patient with acute cholecystitis: Report of a case. *Surgery Today*. 2007 Aug;37(8):713-5.
12. Thejeswi P, Reddy GP, Prabhu S. Gall bladder carcinoma in a young male—a rare presentation. *IOSR Journal of Dental and Medical Sciences*. 2014;13(4):42-5.
13. Gomez-Paz S, Patel S, Rizvon K. An Unusual Case of Gallbladder Cancer in a Young Male: 1392. *Official journal of the American College of Gastroenterology|ACG*. 2018 Oct 1;113:S799.