

Continuous Erector Spinae Plane Block with serratus anterior plane block along with general anaesthesia in a Patient with Multiple Comorbidities Undergoing Modified Radical Mastectomy

¹Dr. Shashi Kiran, Senior Professor, Department of Anesthesiology and Critical Care, PGIMS, Rohtak, Haryana.

²Dr. Geeta Choudhary, Assistant Professor, Department of Anesthesiology and Critical Care, PGIMS, Rohtak, Haryana.

³Dr. Priyanka Bansal, Associate Professor, Department of Anesthesiology and Critical Care, PGIMS, Rohtak, Haryana.

Corresponding Author: Dr. Geeta Choudhary, Assistant Professor, Department of Anesthesiology and Critical Care, PGIMS, Rohtak, Haryana.

Citation this Article: Dr. Shashi Kiran, Dr. Geeta Choudhary, Dr. Priyanka Bansal, “Continuous Erector Spinae Plane Block with serratus anterior plane block along with general anaesthesia in a Patient with Multiple Comorbidities Undergoing Modified Radical Mastectomy”, IJMSIR- April - 2022, Vol – 7, Issue - 2, P. No. 284 – 287.

Type of Publication: Case Report

Conflicts of Interest: Nil

Abstract

Anesthesia in patients with multiple comorbidities is always challenging for anesthesiologists. Moderate-to-severe pain is common after modified radical mastectomy. Good perioperative analgesia (erector spinae and PEC 2 block) in such surgeries enhances recovery, leads to early ambulation, prevents any cardiac event, and decreases chances of chronic pain.

Keywords: Chronic pain, continuous erector spinae block, PEC 2, modified radical mastectomy.

Introduction

Breast cancer (BC) is the most common cancer in women worldwide^{1,2}. Modified radical mastectomy (MRM) involves removal of the whole breast: the skin, areola, nipple and most axillary lymph nodes. During mastectomy, some of the nerves in the chest are severed. Most women have some level of pain in the days after the procedure. Management of patients with multiple comorbidities, especially coronary artery disease (CAD), is challenging for anesthesiologists. Balanced anesthesia with adequate analgesia is of prime importance while

managing such patients to prevent surgical stress response and balance between cardiac oxygen demand and supply. Poor perioperative pain management can lead to increased chances of recurrence of malignancy and development of chronic pain.^[3,4] Regional block for pain management has many advantages in such patients including provision of adequate analgesia, reduced need for opioids, decreased postoperative nausea and vomiting, postoperative pulmonary complications, enhanced recovery, and early ambulation. Ultrasound-guided erector spinae plane (ESP) block is a newer myofascial plane block in which drug is deposited deep to erector spinae muscle that anesthetizes the dorsal and ventral rami and rami communicants of the spinal nerves. Recent studies have shown that a pectoral nerve block can provide a good analgesic effect for pain after Breast Cancer surgery^{5,6}. we report the use of ultrasound-guided ESP block along with PEC2 block as a perioperative analgesic modality in a patient with multiple comorbidities, posted for MRM. Informed consent from the patient was obtained for blocks.

Case report

A 60-year-old, 50-kg female was scheduled for MRM for infiltrating ductal carcinoma of the right breast. She was not a known case of CAD, hypertension (HTN), type II diabetes mellitus (DM). But She had a history of shortness of breath in her daily routine activity (NYHA Class III). she was on cardiac medication (tab dystrophin 10/50 once in a day, tab carvedilol 3.125 twice a day, tab ramipril 2.5 once a day) since 1 month. Preoperative two-dimensional echocardiography showed moderate left ventricular (LV) hypertrophy, LV dilatation, severe left ventricular systolic dysfunction with reduced LV ejection fraction (15%–20%), global hypokinesia and grade 1/4 diastolic dysfunction and regional wall motion abnormality in the apical and lateral walls, mild Tricuspid regurgitation. Her preoperative ECG showed Q-wave and ST-segment depression in the left chest leads.

In the operative room, routine monitoring (ECG, Spo₂, blood pressure) was attached.

Under all aseptic precautions arterial catheter was placed in left radial artery for invasive BP monitoring, a right sided ultrasound guided in plane continuous ESP block at T4-5 level was performed in sitting position. Under all aseptic precautions we inserted an 18 G Touhy needle for erector spinal plane block with direction from cranial to caudal until the tip of the needle hit transverse process of T4 vertebra. location of the needle tip was confirmed by visible lifting of erector spinae muscle after injection of normal saline. A total 20 ml of 0.25% bupivacaine.

in 3-ml aliquots was injected deep to erector muscle and superficial to transverse process, followed by insertion of indwelling catheter through the needle.

A 20 ml 0.25% of bupivacaine in serratus anterior plane block at the level of 2nd and 3rd rib deep to the serratus anterior muscle plane.

Sensory effect after 20 min of injection of local anesthetic (LA) agent was confirmed from dermatomal level T2 to T6. Then patient was turned supine, anesthesia was induced with injection fentanyl 60µg and injection thiopentone 75 mg. Airway was secured with supraglottic airway, i-gel number 4. Maintenance of anesthesia was achieved with isoflurane and air and oxygen mixture (50:50) with the aim of maintaining MAC 0.8–0.9 without the use of muscle relaxant throughout the surgery. The total surgical duration was 140 min. There were no significant changes in vital parameters on surgical skin incision and whole intraoperative period. Infusion of bupivacaine 0.25% of 4ml/h was continued till 48 h postoperatively for analgesia. The ESP catheter was removed after 48 h of surgery. The visual analog score (VAS) score at rest was 1/10 and on movement was 2/10, and the patient was able to ambulate in the ward.

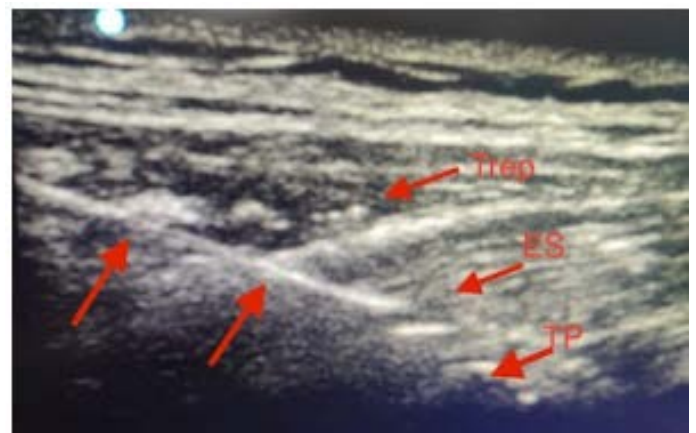


Figure 1: showing erector spinae block with all muscles and needle marked.

Discussion

Systemic administration of opioids and nonsteroidal anti-inflammatory drugs combined with thoracic epidural

(TE) or thoracic paravertebral is usual practice for postoperative pain management for MRM surgery. Although TE is considered as the gold standard for breast surgery, it is challenging to perform in upper thoracic region. It also has chances of dural puncture, hemodynamic instability, epidural hematoma and spinal cord injury. we decided to manage intraoperative as well as postoperative analgesia by ESP and serratus anterior plane block.

The ESP block was first described by Forero. It can be used for acute postoperative pain to chronic neuropathic pain⁷. The transverse processes of the thoracic vertebrae are the main target structures while performing block, which are easily identified with high-frequency linear or a low-frequency curved array transducer depending on weight and body habitus of the patient. LA drug is injected deep to erector spinae muscle which is a group of three muscles including iliocostalis, longissimus, and spinalis. It extends from sacrum and lumbar spinous processes up to C2 cervical vertebrae, encased in aponeurosis called as thoracolumbar fascia⁸. The columnar arrangement of erector muscle leads to extensive craniocaudal spread of drug.

Diffusion of LA into the paravertebral space is the main postulated mechanism of analgesic action of ESP Block. It acts at both the ventral and dorsal rami of the thoracic spinal nerves, as well as at the rami communicants that contain sympathetic nerve fibers and thus provide analgesia along the posterior, lateral, and anterior thoracic walls.

Since our patient was with low ejection fraction, paramount importance was given to provide excellent analgesia in perioperative period to prevent surgical stress response, avoid opioids as postoperative analgesia as they produce respiratory depression, and hamper early

recovery and ambulation. We choose ESP along with serratus anterior plane block in this patient because landmarks were difficult to identify for epidural catheter placement. It is simpler to perform, provide equivalent analgesic efficacy with no additional side effects and better safety profile. The chances of pleural puncture are very less in ESP block in comparison to paravertebral block because drug injection site is at the level of transverse process of corresponding vertebra. The rest of the complications mentioned in literature are similar to other continuous blocks such as catheter migration, accidental breakage or removal of catheter, and LA toxicity on prolonged infusion. In our patient none of these were observed.

Conclusion

The ESP block along with serratus anterior plane block is a suitable alternative to thoracic epidural and paravertebral blocks to reduce aesthetic requirement and to provide intra and post op analgesia along with general anesthesia in MRM. It also helps in compromised cardiac conditions with lesser incidence of complications.

References

1. Siegel RL, Miller KD, Jemal A. Cancer statistics, 2018. *CA Cancer J Clin.* 2018;68 (1):7–30. doi:10.3322/caac.21442 [PubMed] [CrossRef] [Google Scholar]
2. Chen W, Zheng R, Baade PD. Cancer statistics in China, 2015. *CA Cancer J Clin.* 2016;66(2):115–132. doi:10.3322/caac.21338 [PubMed] [CrossRef] [Google Scholar]
3. Calì Cassi L, Biffoli F, Francesconi D, Petrella G, Buonomo O. Anesthesia and analgesia in breast surgery: The benefits of peripheral nerve block. *Eur Rev Med Pharmacol Sci* 2017; 21:1341-5.

4. Bokhari F, Sawatzky JA. Chronic neuropathic pain in women after breast cancer treatment. *Pain Manag Nurs* 2009; 10:197-205.
5. Karaca O, Pinar HU, Arpacı E, Dogan R, Cok OY, Ahiskalioglu A. The efficacy of ultrasound- guided type-I and type-II pectoral nerve blocks for postoperative analgesia after breast augmentation: a prospective, randomised study. *Anaesth Crit Care Pain Med*. 2019;38(1):47–52. Doi: 10.1016/j.accpm.2018.03.009 [PubMed] [CrossRef] [Google Scholar]
6. Blanco R. The ‘pecs block’: a novel technique for providing analgesia after breast surgery. *Anaesthesia*. 2011;66(9):847–848. doi:10.1111/ j.1365-2044.2011.06838.x [PubMed] [CrossRef] [Google Scholar]
7. Forero M, Adhikary SD, Lopez H, Tsui C, Chin KJ. The erector spinae plane block: A Novel analgesic technique in thoracic neuropathic pain. *Reg Anesth Pain Med* 2016; 41:621-7.
8. Willard FH, Vleeming A, Schuenke MD, Danneels L, Schleip R. The thoracolumbar fascia: Anatomy, function and clinical considerations. *J Anat* 2012; 221:507-36.