

Study of Acute Myeloid Leukemias in a tertiary care hospital

¹Dr. Aparajita Sur, ²Dr Ujwala Maheshwari, ³Dr.Naresh Kulkarni, ⁴Dr. Vrutika Shah

¹⁻⁴MGM Hospital, Kamothe, Navi Mumbai

Corresponding Author: Dr. Aparajita Sur, MGM Hospital, Kamothe, Navi Mumbai

Citation this Article: Dr. Aparajita Sur, Dr Ujwala Maheshwari, Dr.Naresh Kulkarni, Dr. Vrutika Shah, “Study of Acute Myeloid Leukemias in a tertiary care hospital”, IJMSIR- November - 2021, Vol – 6, Issue - 6, P. No. 161 – 164.

Type of Publication: Original Research Article

Conflicts of Interest: Nil

Introduction

Acute myeloid leukaemia (AML) is a heterogeneous disorder characterized by clonal expansion of myeloid progenitors (blasts) in the bone marrow and peripheral blood.

Previously incurable, AML is now cured in approximately 35%–40% of patients younger than age 60 years old. It is a heterogeneous hematologic malignancy characterized by clonal expansion of myeloid blasts in the peripheral blood, bone marrow, and/or other tissues, which leads to impaired production of normal blood cells.¹

Thus, leukemic cell infiltration in the marrow invariably leads to bone marrow failure manifesting in the form of anaemia or thrombocytopenia, while absolute neutrophil count may be low or normal, depending on the total white cell count.

AML accounts for approximately 20% of acute leukaemia in children and 80% of acute leukemia in adults.

Aims and Objectives

To study the morphology of various lymphoid and myeloid cells in acute leukaemia cases.

Materials and Methods

Peripheral blood samples: 2 ml of venous blood was withdrawn into EDTA tube for complete blood count. Hemoglobin estimation, packed cell volume and red blood cell count was done by automated analyzer. White blood cell count and platelet count was done using Automated analyzer The typing of anemia was done by automated analyzer and peripheral blood smear stained by Leishman Stain.

The present study, a prospective study which includes review of clinical records of newly diagnosed cases of Acute Myeloid Leukaemia admitted in a tertiary care teaching hospital of MGM’s Medical College in Navi Mumbai. The study consists of examination of all the available clinical data, cell morphology on peripheral smear. The diagnosis of all cases were subjected to medical history taking (fever, bleeding tendency, therapeutic history and blood transfusion) and clinical examination (organomegaly and lymphadenopathy).Some cases underwent flow cytometric analysis using 3 colour flow cytometer.

Inclusion Criteria

The diagnosed cases of Acute Myeloid Leukaemia admitted in a tertiary care teaching hospital of MGM’s

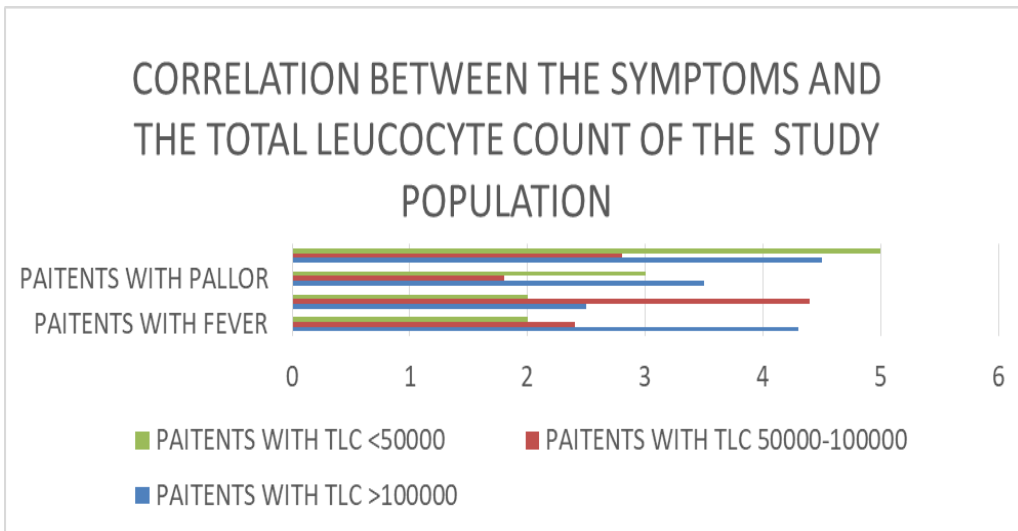
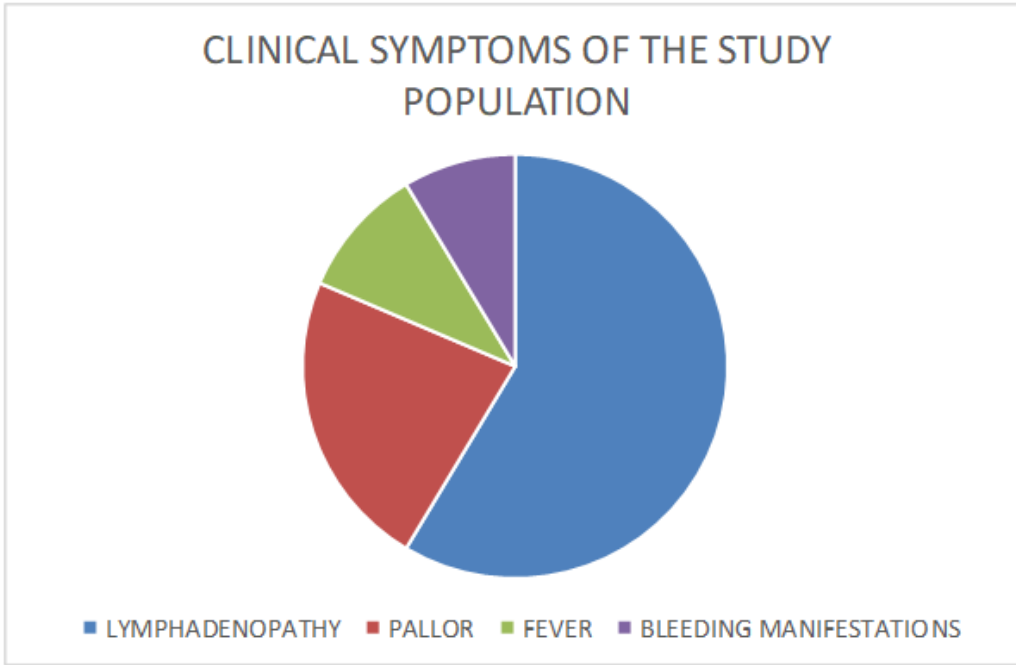
Medical College in Navi Mumbai region of Maharashtra state of India.

Exclusion Criteria

Patients unwilling to give consent for the research study admitted to tertiary care hospital. Patients who dropped

out of the study before complete workup, due to death or discharge against medical advice.

Observation



| Sn. | Age | Male | Female | Hemoglobin (g/dl) | TLC(cells /cumm) | Platelet count (Lakhs) | Blast(%) | MPO staining | Flowcytometric analysis | Diagnosis |
|-----|------|------|--------|-------------------|------------------|-------------------------|----------|--------------|-------------------------------|------------------------------|
| 1. | 6yr | M | - | 10.6 | 57,910 | 1.05 | 35% | Negative | | Acute Lymphoblastic Leukemia |
| 2. | 82yr | M | - | 6.9 | 10100 | 51000 | 50% | Positive | CD 38+, CD 13+,CD 33+ | Acute Myeloid Leukemia |
| 3. | 34yr | M | - | 7.2 | 1,01,590 | 26000 | 73% | Positive | | Acute Leukemia |
| 4. | 40yr | M | - | 8.7 | 3,10,730 | 1.47 | 2% | Positive | | Chronic Myeloid Leukemia |
| 5. | 3 yr | - | F | 6.1 | 52,8150 | 4.84 | 38% | Positive | | Acute Leukemia |
| 6. | 19yr | M | - | 8.2 | 4890 | 40000 | 38% | positive | | Acute Leuemia |
| 7. | 18 | M | - | 9.5 | 62630 | 10000 | 30% | Positive | HLA- DR+,CD 33+,CD117+, CD34+ | Acute Myeloid Leukemia |
| 8. | 20 | M | - | 4.9 | 1,34,140 | 16000 | 30% | positive | | Acute Leukemia |
| 9. | 55 | - | F | 4.2 | 88420 | 25000 | 48% | positive | | Acute Leukemia |
| 10. | 37 | - | F | 8.3 | 23000 | 22000 | 61% | Positive | CD33+, CD7+, CD13+, CD64+ | Acute Myeloid Leukemia |

Among the cases studied , some presented with generalised body ache and weakness for which radiological investigations were done which was suggestive of Leukaemia.

Coronal sections of sacroiliac joints a 40 year old female showing diffuse a)T1 hypo and b)STIR (Fig 1 and Fig 2.)iso to hyper signal bone marrow intensities suggestive of infiltrating changes of yellow bone marrow consistent with Leukaemia

Fig 1: T1 Hypo image Fig 2. STIR image showing infiltrating changes of yellow bone marrow .

Coronal images of a 55 year old male of bilateral hips showing a)T1 hypo and b)STIR iso to hyper signal intensities suggestive of marrow infiltration in axial skeleton seen with leukaemia.

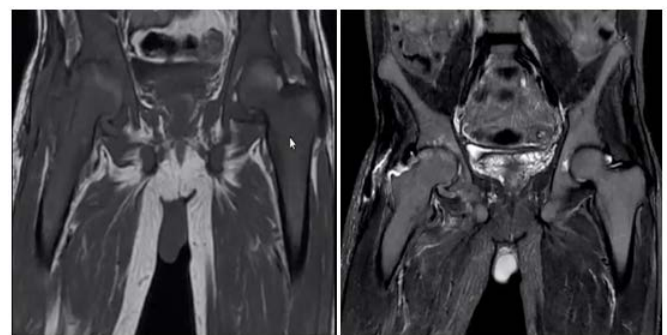
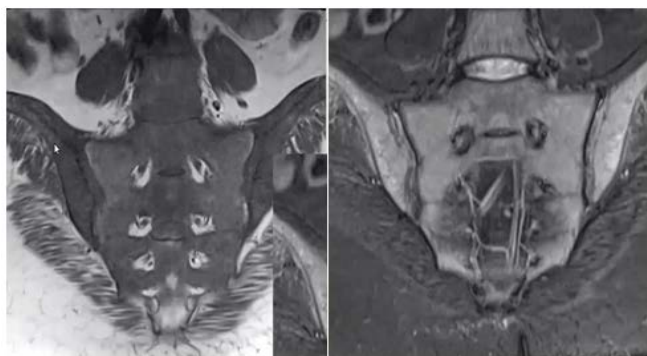

Fig 3. T1 hypo Fig 2. STIR image showing marrow infiltration in axial skeleton.

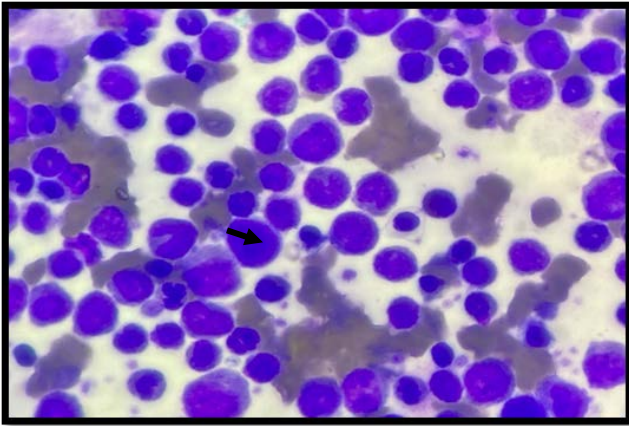


Fig 4: Showing Myeloid Precursor cells (Myeloblast) on Peripheral smear (100x H&E) shown with arrow.

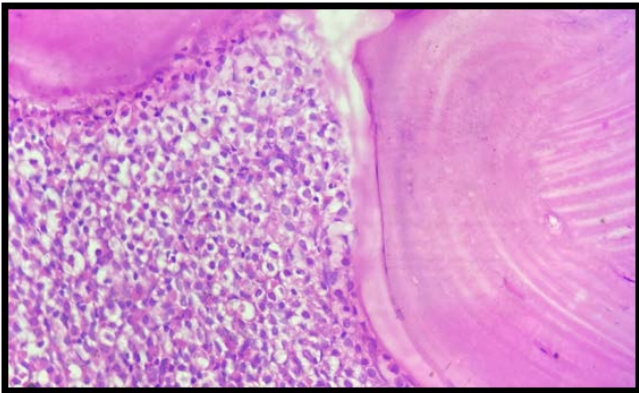


Fig 5: Bone marrow trephine biopsy of the same patient showing proliferation of myeloid precursors.

Conclusion

In the present study there were 10 cases of Acute Leukemias which were all Myeloid series predominant.

The mean age of presentation was 30-40 years with range of 5-70 years

Acute Myeloid Leukemia was more common in male patients

All the cases of AML showed blast cells count more than 20 %.

Lymphadenopathy was the most common clinical manifestation in the study population followed by fever.

Mean Hb% in these cases were

Mean TLC in these cases were

References

1. Shoket N, Muzamil J, Zargar TB, Wani B, Toka V, Bhat JR, et al. Clinical profile of acute myeloid leukemia in North India and utility of nontransplant measures in its management. *Indian J Med Paediatr Oncol* 2019;40:S44-53.
2. Jennifer N. Saultz 1 and Ramiro Garzon 2 et al. Acute Myeloid Leukemia: A Concise Review. *J. Clin. Med.* 2016, 5, 33; doi:10.3390/jcm5030033
3. Bain, Barbara J (2010). *Leukemia diagnosis* 4th edition.
4. Singh, Tejinder(2018) *Atlas and Text of Hematology*
5. *International Journal of Advances in Medicine* Aparna SK et al. *Int J Adv Med.* 2018 Apr;5(2):361-365
6. Watts J and Nimer S. Recent advances in the understanding and treatment of acute myeloid leukemia [version 1; referees: 3 approved] *F1000Research* 2018, 7(F1000 Faculty Rev):1196 (doi: 10.12688/f1000research.14116.1)
7. Gert J. Ossenkoppele, Arjan A. van de Loosdrecht and Gerrit Jan Schuurhuis Department of Haematology, VU University Medical Center, Amsterdam, the Netherlands
8. *Iranian Journal of Pediatric Hematology Oncology* Vol4.No4 Masoumi-Dehshiri R MD1 , Hashemi AS MD2 ,*, Neamatzadeh H MSc2 , Zare-Zardeini H MSc2